

9 December 2021

# Portal inflammation in NAFLD – When to suspect a second pathology?

**Dina G. Tiniakos**



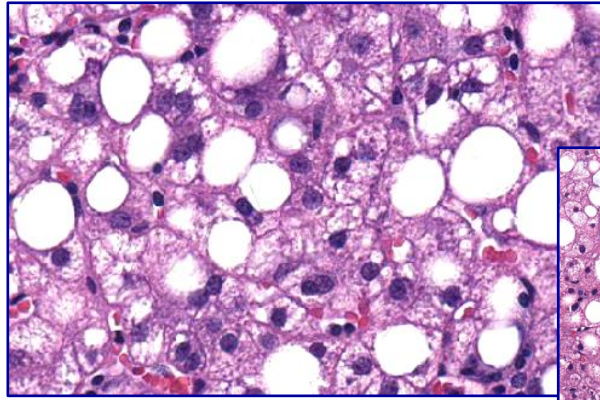
*Translational and Clinical Research Institute,  
Faculty of Medical Sciences,  
Newcastle University, UK*



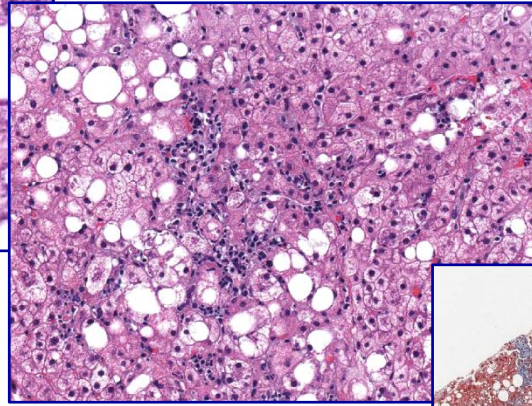
*Dept of Pathology, Aretaieion Hospital,  
National & Kapodistrian University of Athens, Greece*



# Histological spectrum of **NAFLD**

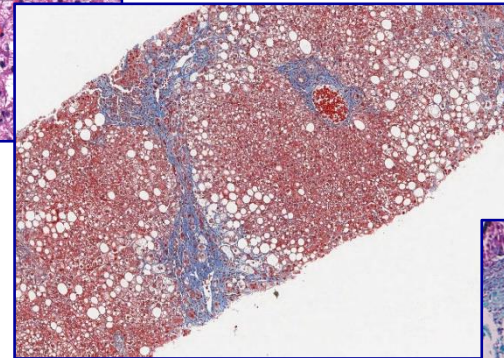


Steatosis **100%**

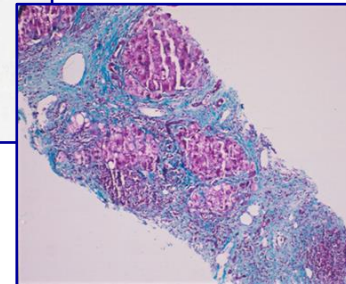


Steatohepatitis  
**(NASH)**

7% Asia  
30% North America  
1.5-6.5% globally



Progressive fibrosis **40% of NASH**



Cirrhosis **3-5%**

*Diehl & Day, NEJM 2017*

*Anstee, Nat Rev Gastro Hepatol 2019*

## • **HCC development**

- NASH/cryptogenic cirrhosis

- **non-cirrhotic NAFLD**

Incidence

2.6-11.3%

0.04-6%

*Huang, Nat Rev Gastroenterol Hepatol 2021*

# Current concepts in NAFLD pathology

**Liver biopsy is the “best” standard**

- **diagnosis of NASH and classification of NAFLD**

*EASL-ESD-EASO NAFLD Clinical Practice Guidelines 2016*

*AASLD NAFLD Practice Guidance 2018*

*Cotter & Rinella, Gastroenterology 2020*

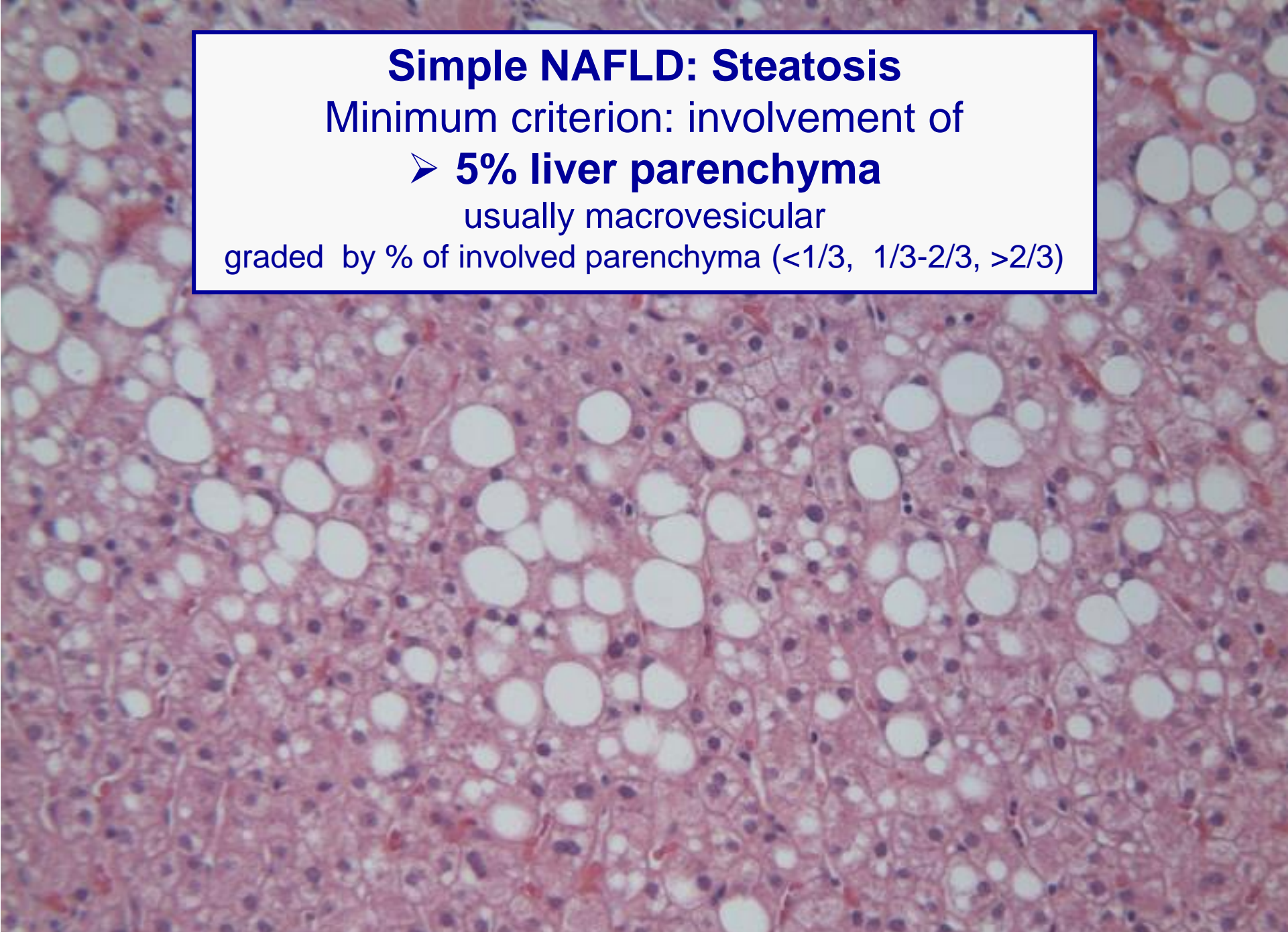
## Simple NAFLD: Steatosis

Minimum criterion: involvement of

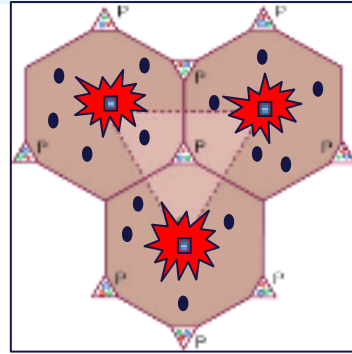
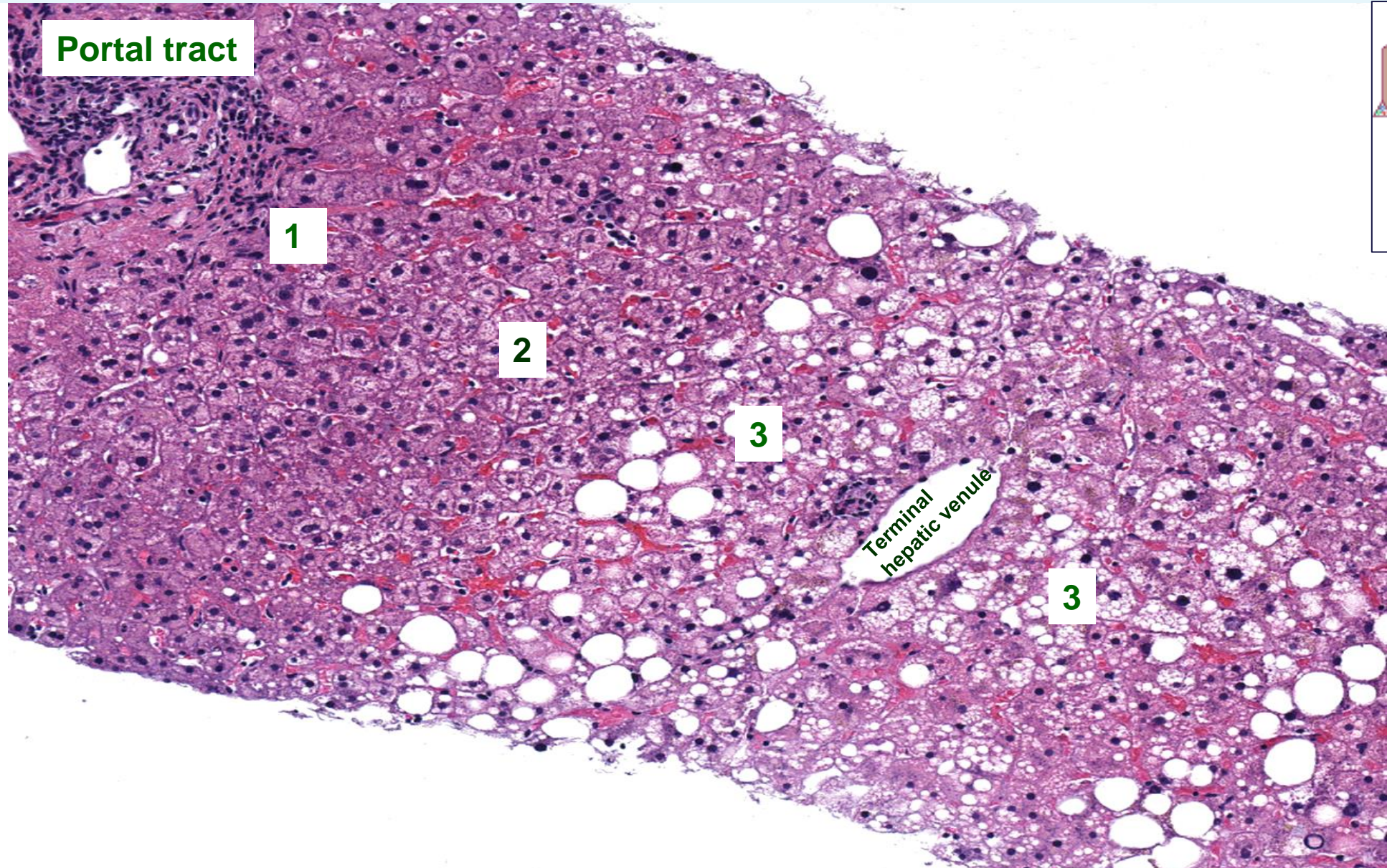
➤ **5% liver parenchyma**

usually macrovesicular

graded by % of involved parenchyma (<1/3, 1/3-2/3, >2/3)

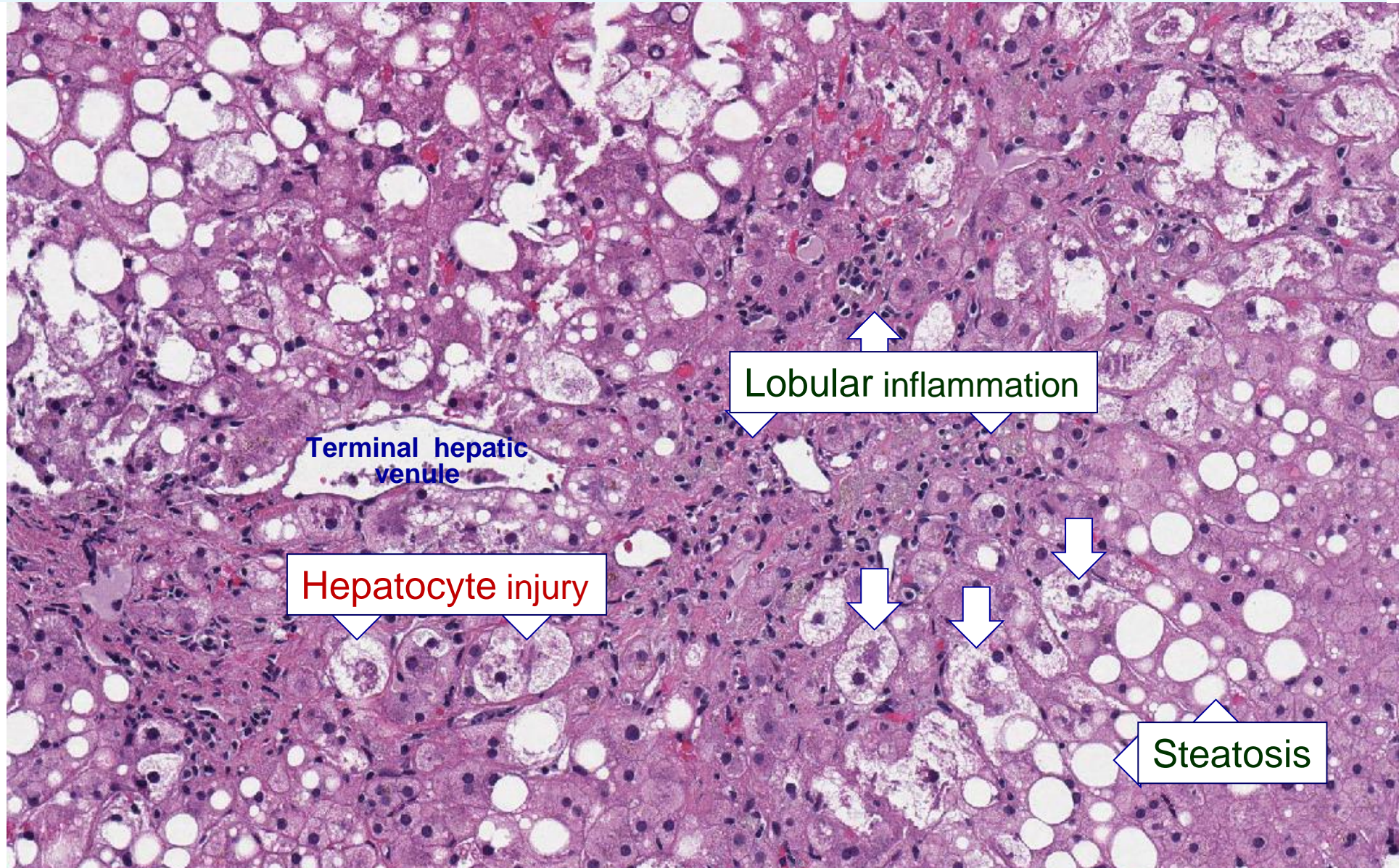


# Adult NASH: Zone 3 predominance of the lesions



# Minimal criteria for diagnosis of adult NASH

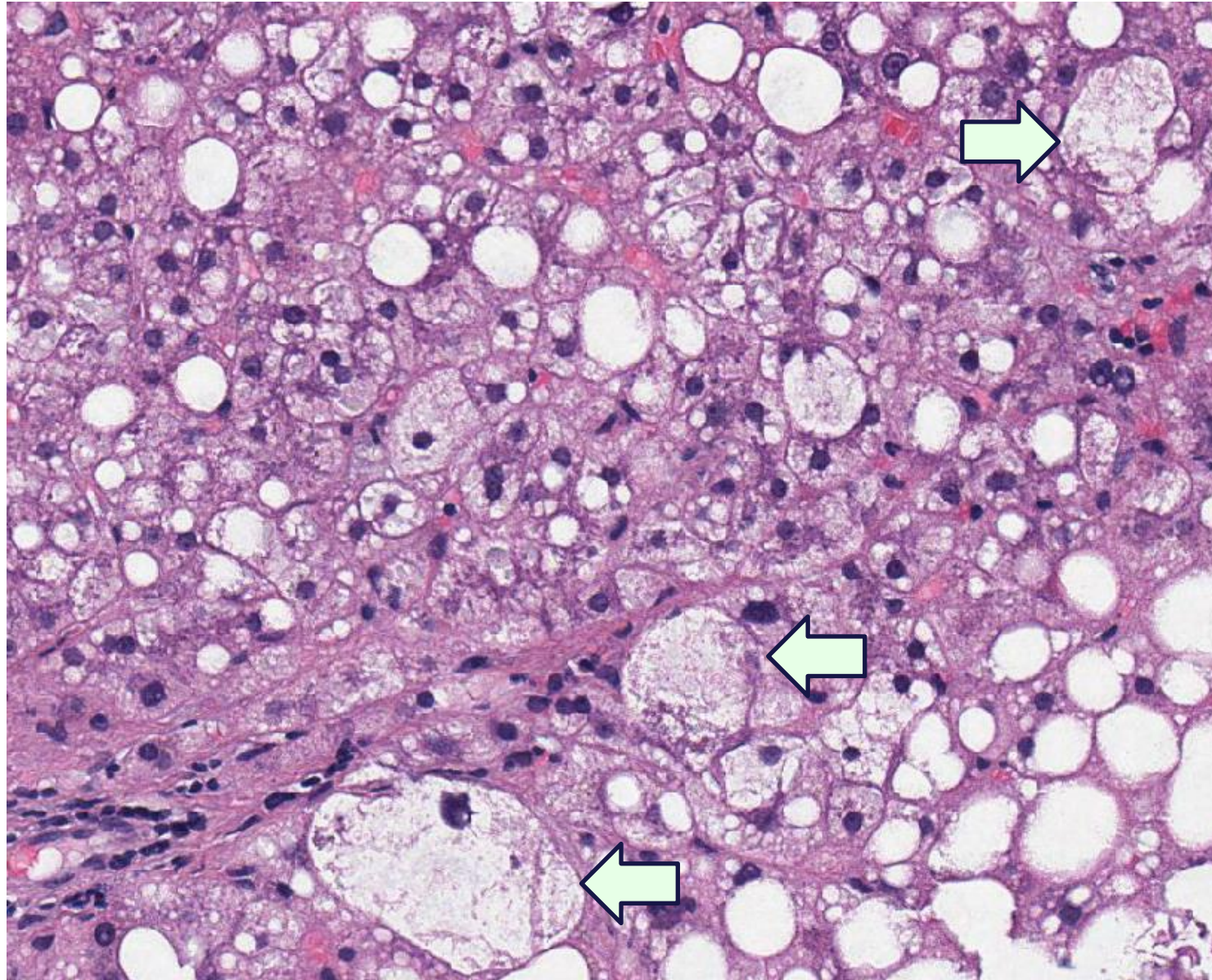
## Constellation of findings



# NASH: Hepatocyte Ballooning Feature required for the diagnosis

Zone 3

Terminal  
hepatic  
venule



# Current concepts in NAFLD pathology

## Liver biopsy is the “best” standard

- diagnosis of NASH and classification of NAFLD
- **assessment of necroinflammatory injury – grading NAFLD activity**

NAFLD Activity Score 0-8

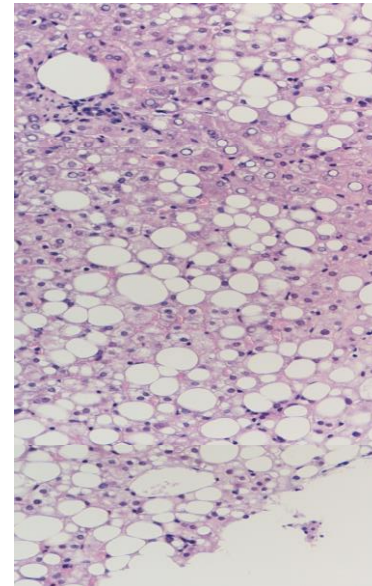
*Steatosis+Lobular Inflammation+Ballooning*

*Kleiner D et al, Hepatology 2005*

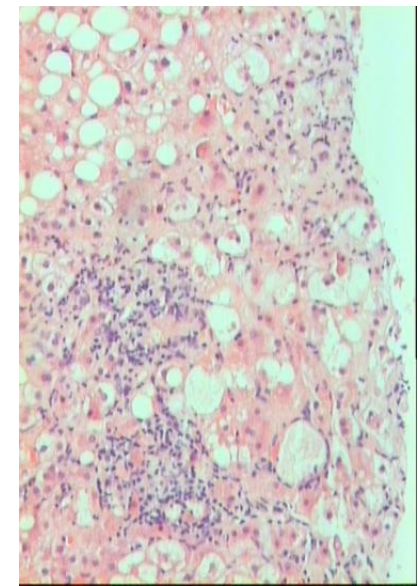
SAF activity score 0-4

*Lobular inflammation+Ballooning*

*Bedossa P et al, Hepatology 2012*



NAS 3  
SAF A1



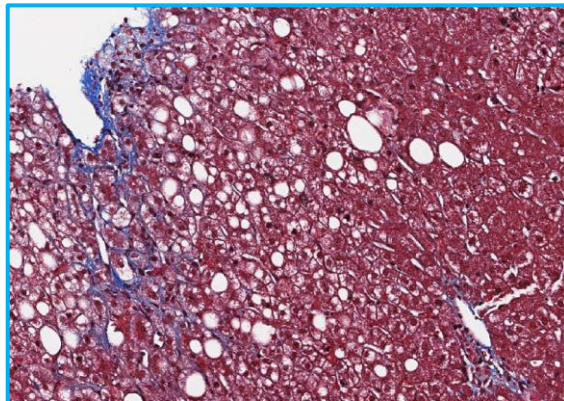
NAS 7  
SAF A4

# Current concepts in NAFLD pathology

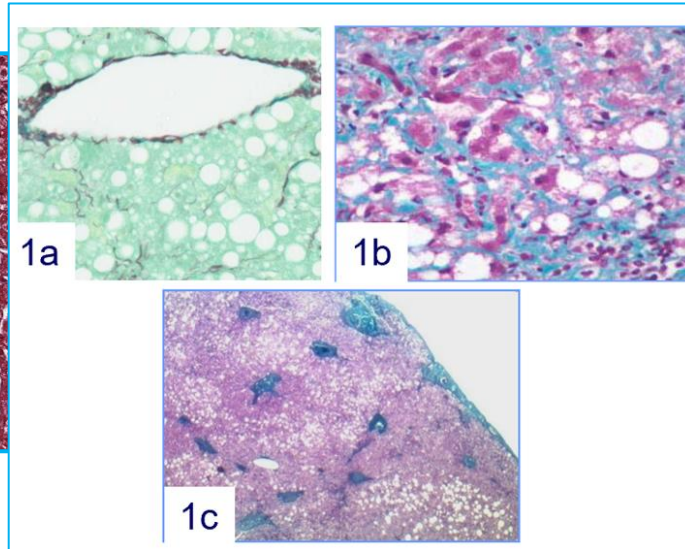
## Liver biopsy is the “best” standard

- diagnosis of NASH and classification of NAFLD
- assessment of necroinflammatory injury – grading NAFLD activity
- **evaluation of extent of fibrosis and architectural remodeling – staging fibrosis**

Semi-quantitative staging systems  
*Brunt EM et al, Am J Gastroenterol 1999*  
*Kleiner D et al, Hepatology 2005*



**F1** Zone 3 sinusoidal/  
pericellular  
fibrosis-Z3PCF

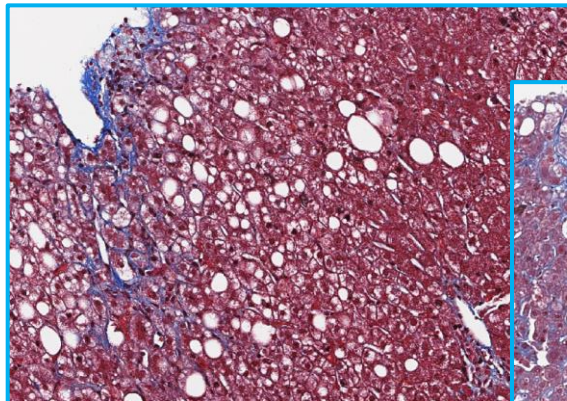


# Current concepts in NAFLD pathology

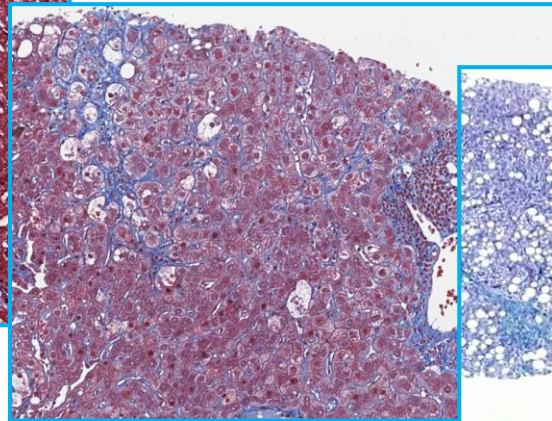
## Liver biopsy is the “best” standard

- diagnosis of NASH and classification of NAFLD
- assessment of necroinflammatory injury – grading NAFLD activity
- evaluation of extent of fibrosis and architectural remodeling – **staging fibrosis**

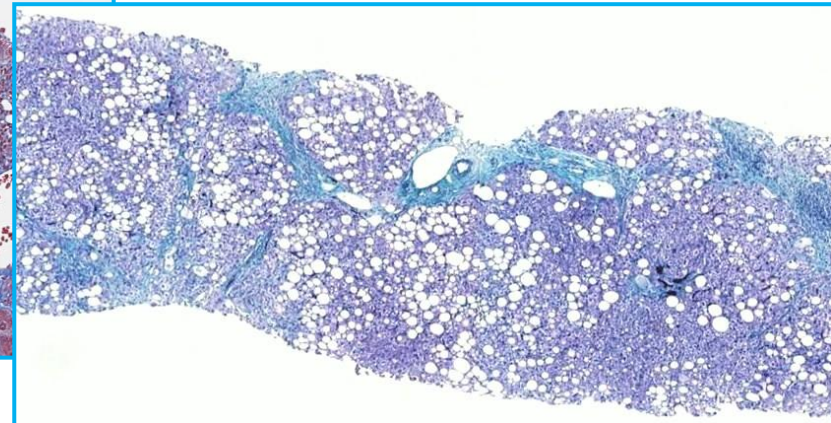
Semi-quantitative staging systems  
*Brunt EM et al, Am J Gastroenterol 1999*  
*Kleiner D et al, Hepatology 2005*



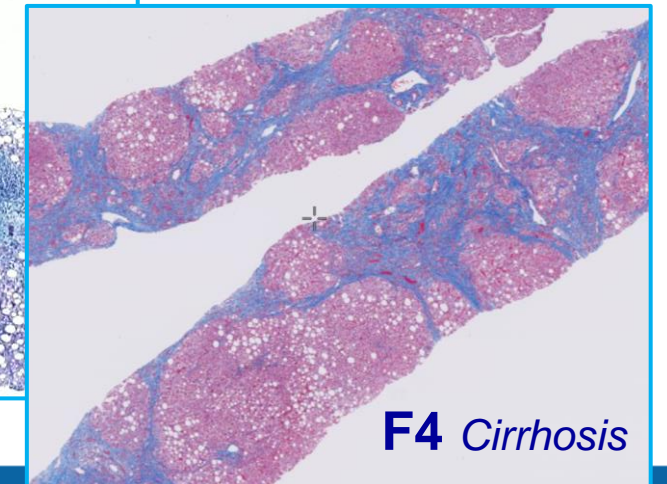
**F1** Zone 3 sinusoidal/  
pericellular  
fibrosis-Z3PCF



**F2** Z3PCF &  
periportal fibrosis



**F3** Bridging fibrosis




**F4** Cirrhosis

# Current concepts in NAFLD pathology

## Liver biopsy is the “best” standard

- diagnosis of NASH and classification of NAFLD
- assessment of necroinflammatory injury – grading NAFLD activity
- evaluation of extent of fibrosis and architectural remodeling – **staging fibrosis**

Semi-quantitative staging systems  
*Brunt EM et al, Am J Gastroenterol 1999*  
*Kleiner D et al, Hepatology 2005*



**Fibrosis stage is a key independent prognostic marker for all-cause and liver-related mortality in NAFLD patients**

**F1** Zone 3 sinusoidal pericellular fibrosis-Z3F


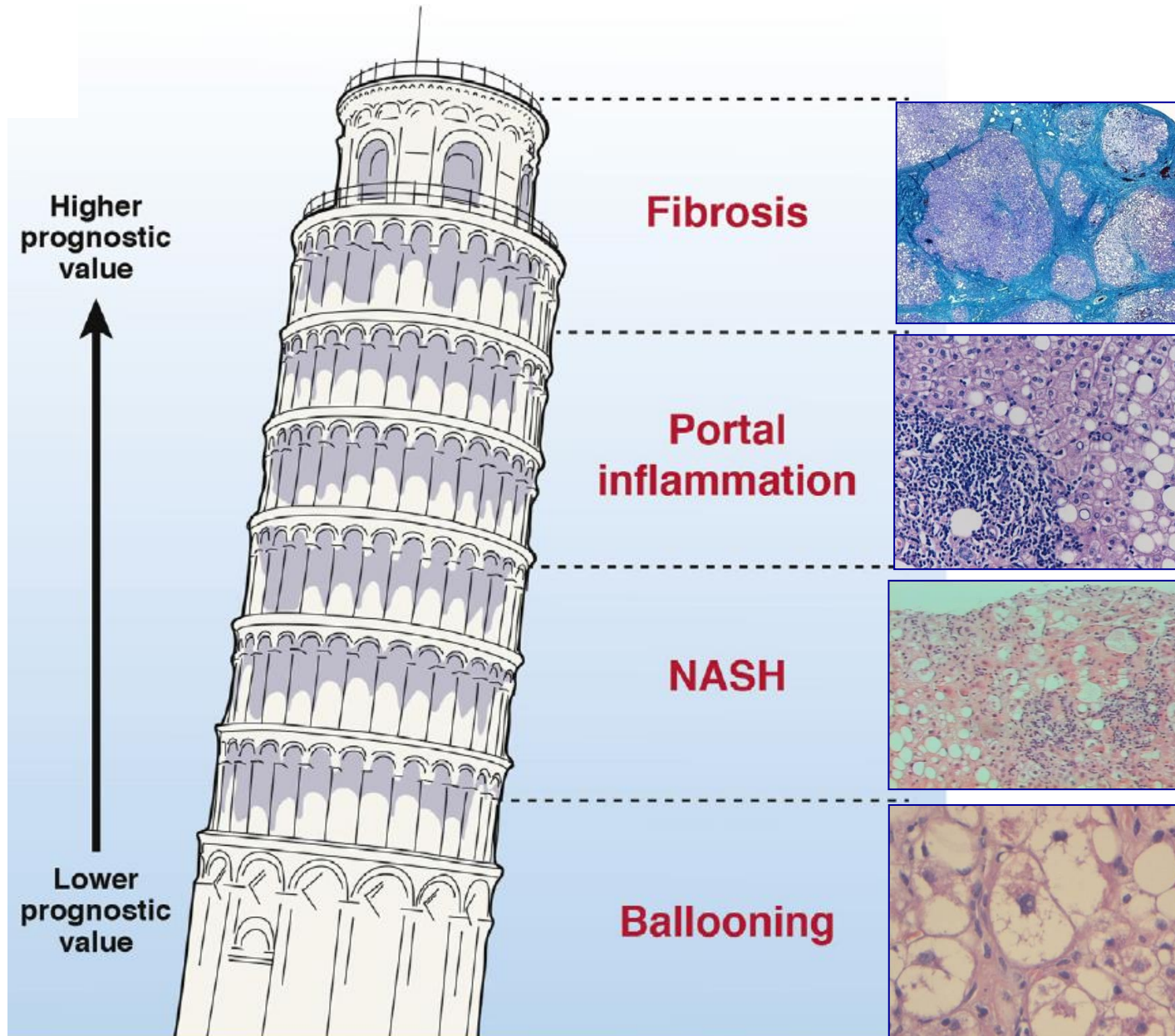
*Taylor R et al, Gastroenterology 2020 Meta-analysis*

pericellular fibrosis

**F3** Bridging fibrosis

**F4** Cirrhosis

# Prognostic significance of histological features of NAFLD

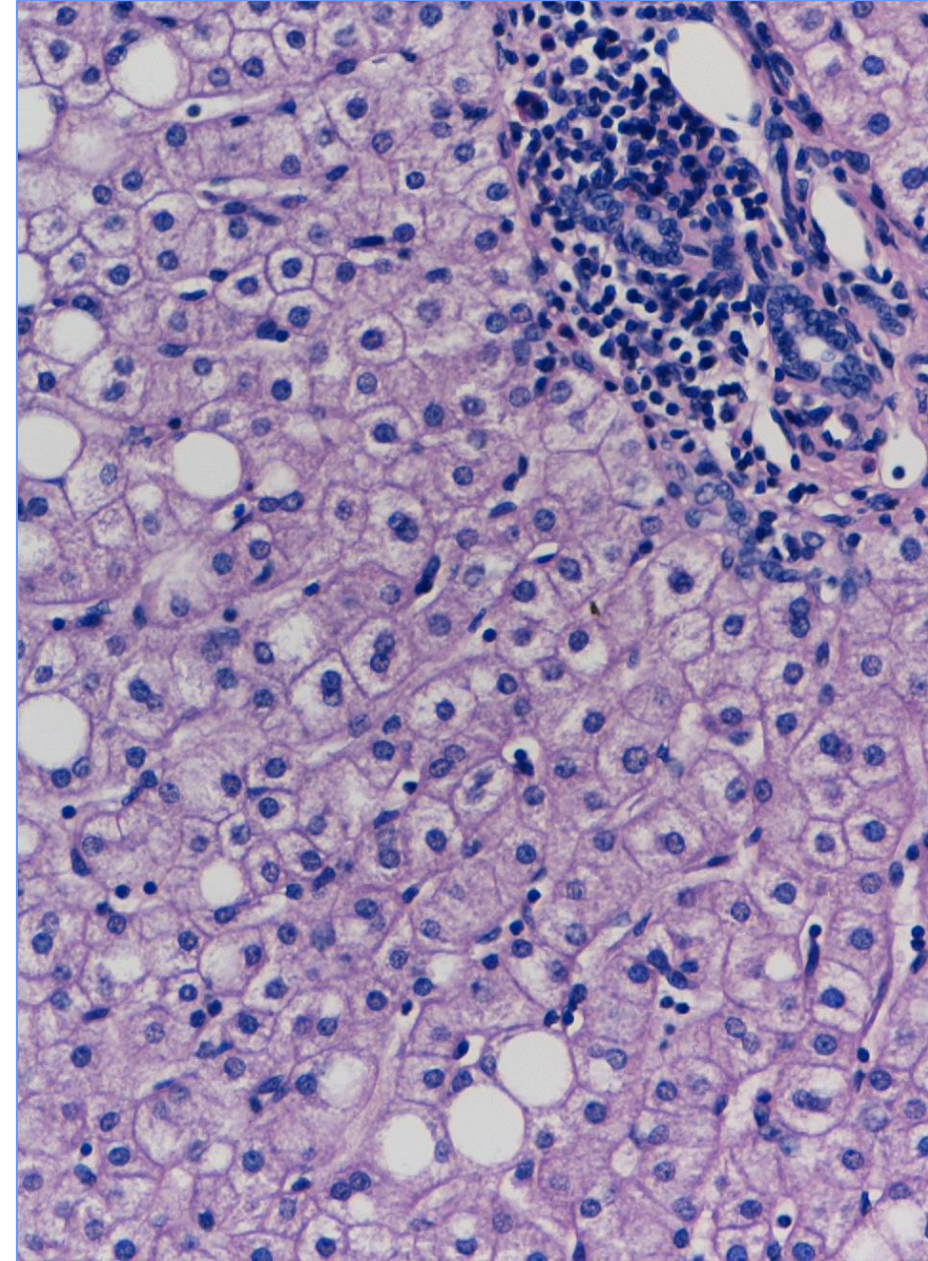


*Loomba, Gastroenterology 2015  
Angulo, Hepatology 2015*

# Adult NAFLD: Portal inflammation

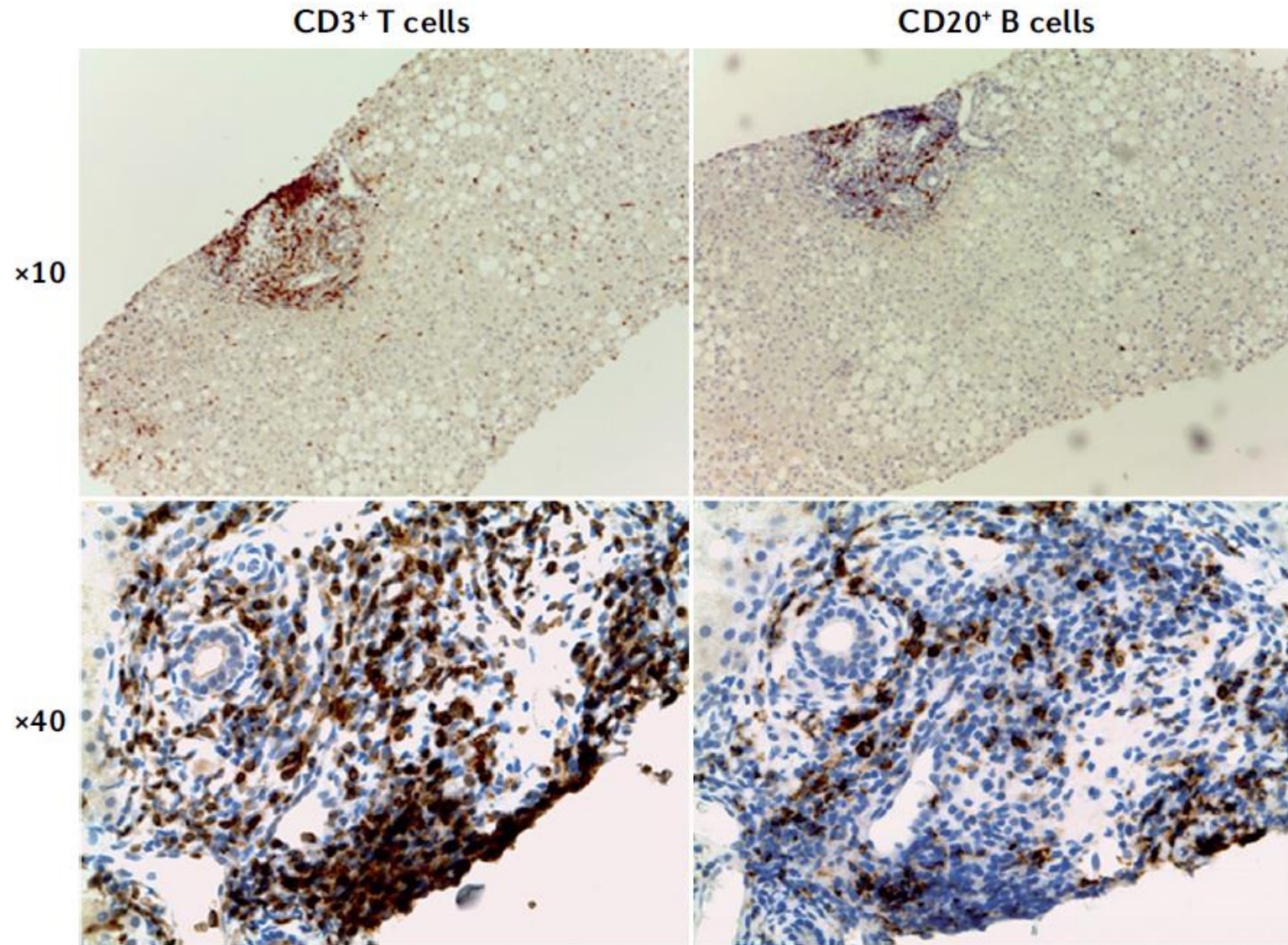
May be seen in addition to lobular inflammation

- usually minimal or mild



# Adult NAFLD: Portal inflammation

May be seen in addition to lobular inflammation



# Adult NAFLD: Portal inflammation

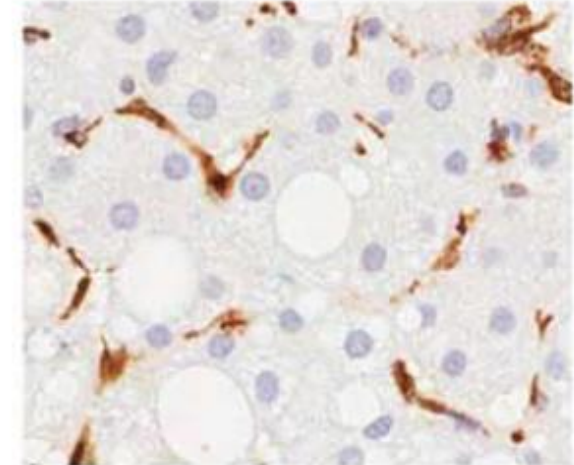
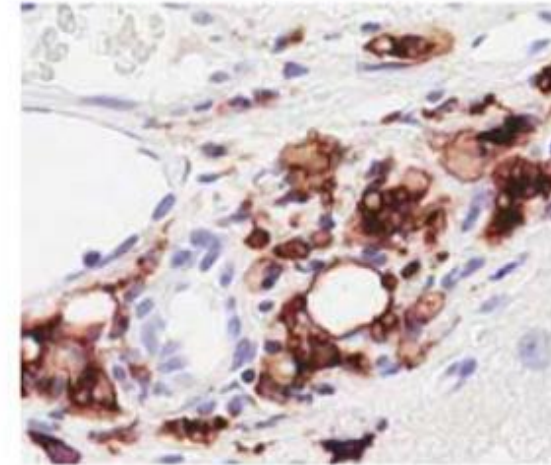
May be seen in addition to lobular inflammation

- usually minimal or mild
- T lymphocytes & macrophages predominate at all stages
- B lymphocytes and plasmacytes are also present
- **↑ portal macrophages** is the **earliest inflammatory change** observed in simple steatosis

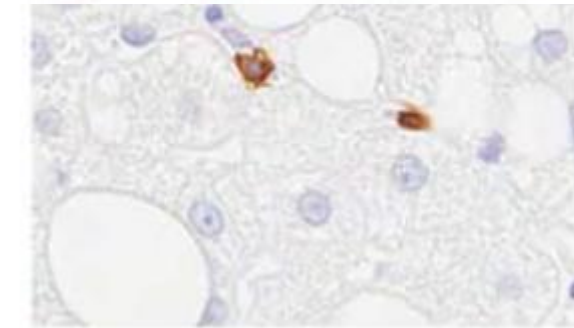
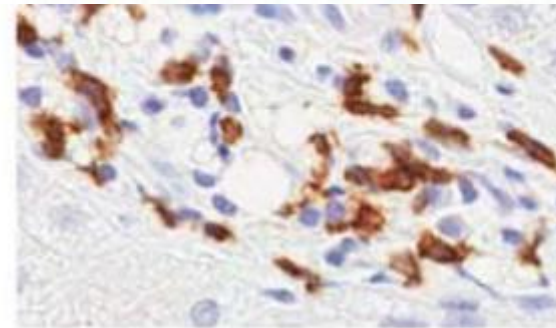
Portal

Lobular

CD68



CD8



# Adult NAFLD: Portal inflammation

May be seen in addition to lobular inflammation

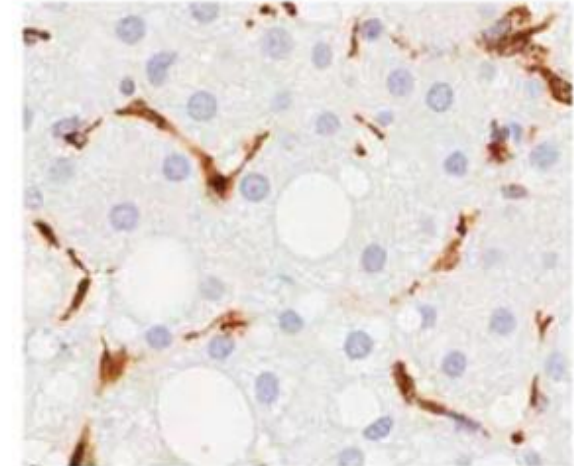
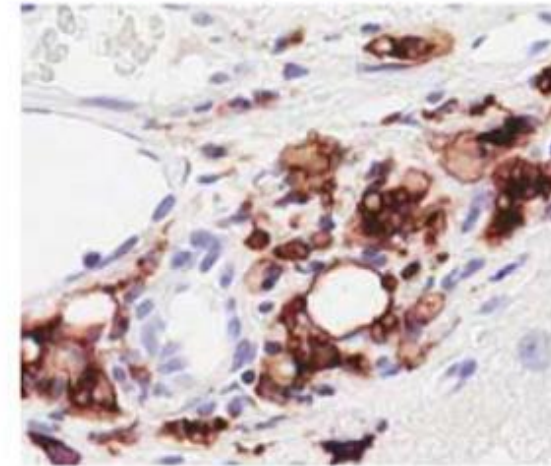
- usually minimal or mild
- T lymphocytes & macrophages predominate at all stages
- ↑ portal macrophages is the earliest inflammatory change observed in simple steatosis

**Early macrophage infiltration  
and subsequent  
portal inflammation may play a  
role in NAFLD progression**

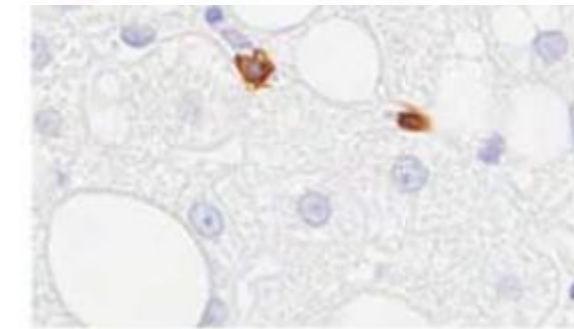
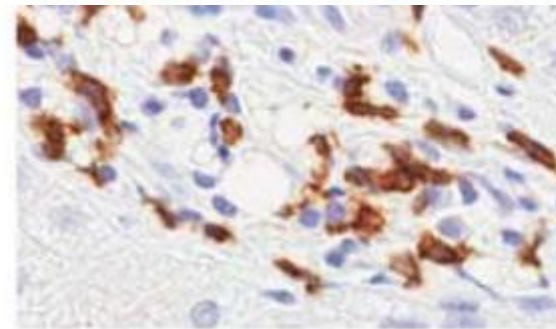
Portal

Lobular

CD68

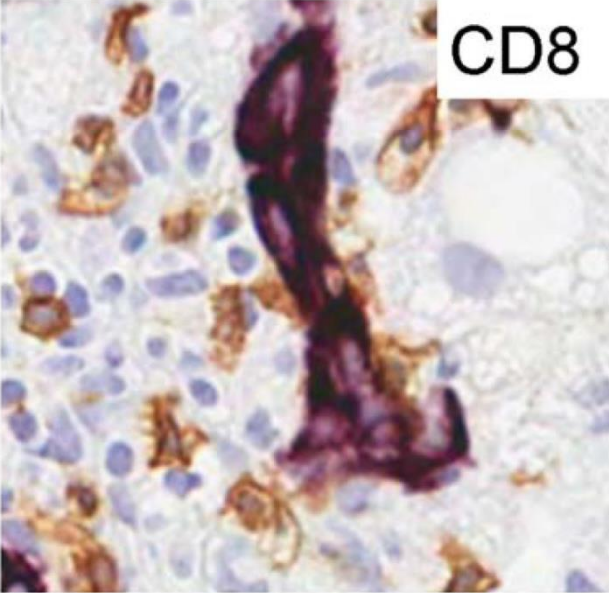


CD8



# NASH: Portal inflammation correlates with ductular reaction and hepatic progenitor cell (HPC) activation

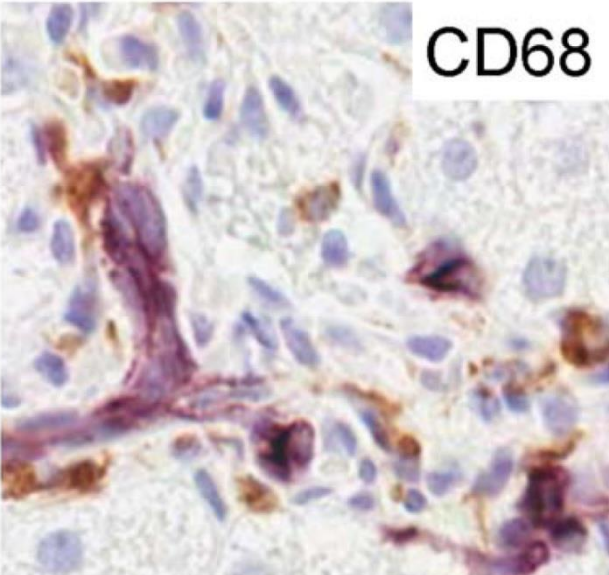
CD8



- The inflammatory niche in portal tracts may drive the fate of HPC
- T cells and macrophages in close contact with proliferating bile ductules

*Gadd, Hepatology 2014*

CD68

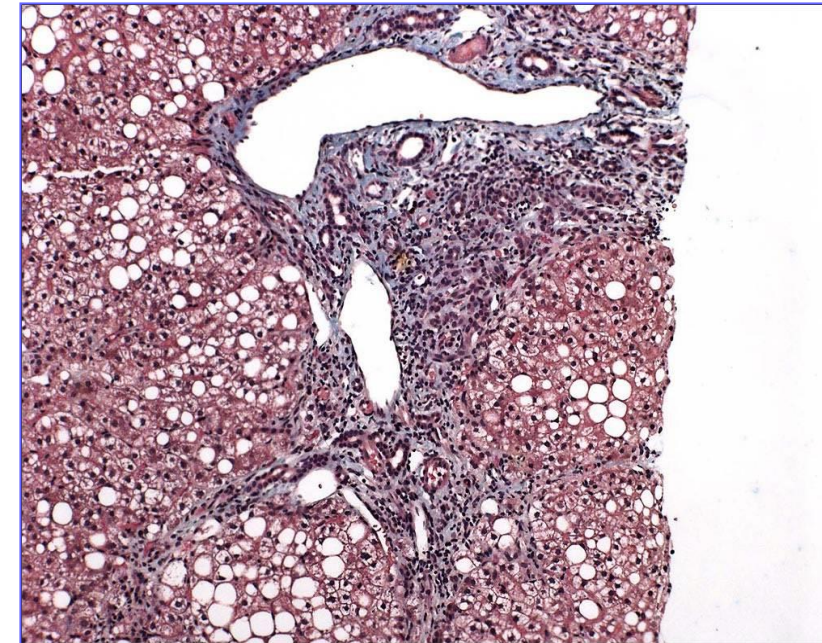


- **Portal inflammation may drive fibrogenesis in NAFLD:**

- by releasing profibrogenic cytokines
- by determining the fate of HPC towards fibrogenic ductular reaction

*Gadd, Hepatology 2014*

*Carotti, J Clin Pathol 2015*



# Nonalcoholic Steatohepatitis: A Proposal for Grading and Staging the Histological Lesions

THE AMERICAN JOURNAL OF GASTROENTEROLOGY  
Vol. 94, No. 9, **1999**

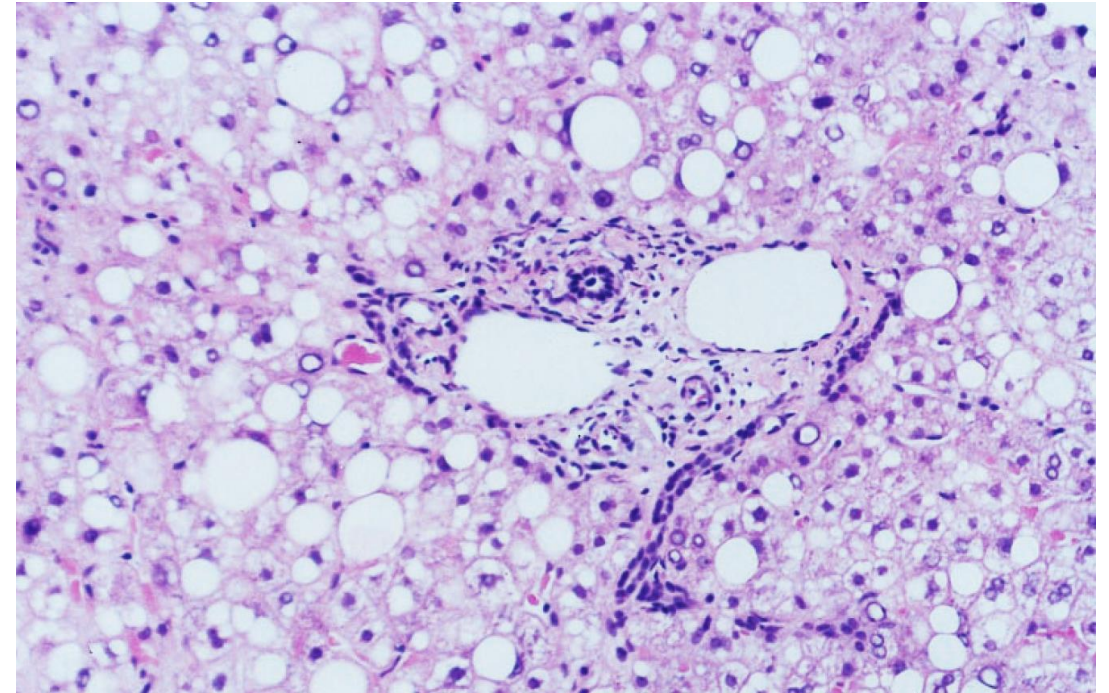
Elizabeth M. Brunt, M.D., Christine G. Janney, M.D., Adrian M. Di Bisceglie, M.D., Brent A. Neuschwander-Tetri, M.D., and Bruce R. Bacon, M.D.

*Department of Pathology and Division of Gastroenterology and Hepatology, Department of Medicine, Saint Louis University School of Medicine, St. Louis, Missouri*

## **51 biopsies with NASH (50 patients)**

4. *Portal tract inflammation* was graded as none, mild, moderate, and severe (0–3); types of inflammatory cells were noted (lymphocytes, plasma cells, eosinophils).

nearly always present. Portal inflammation is at least mild; it may be moderate and interface activity may be seen.



Mild portal inflammation (Brunt et al, 1999)

# Nonalcoholic Steatohepatitis: A Proposal for Grading and Staging the Histological Lesions

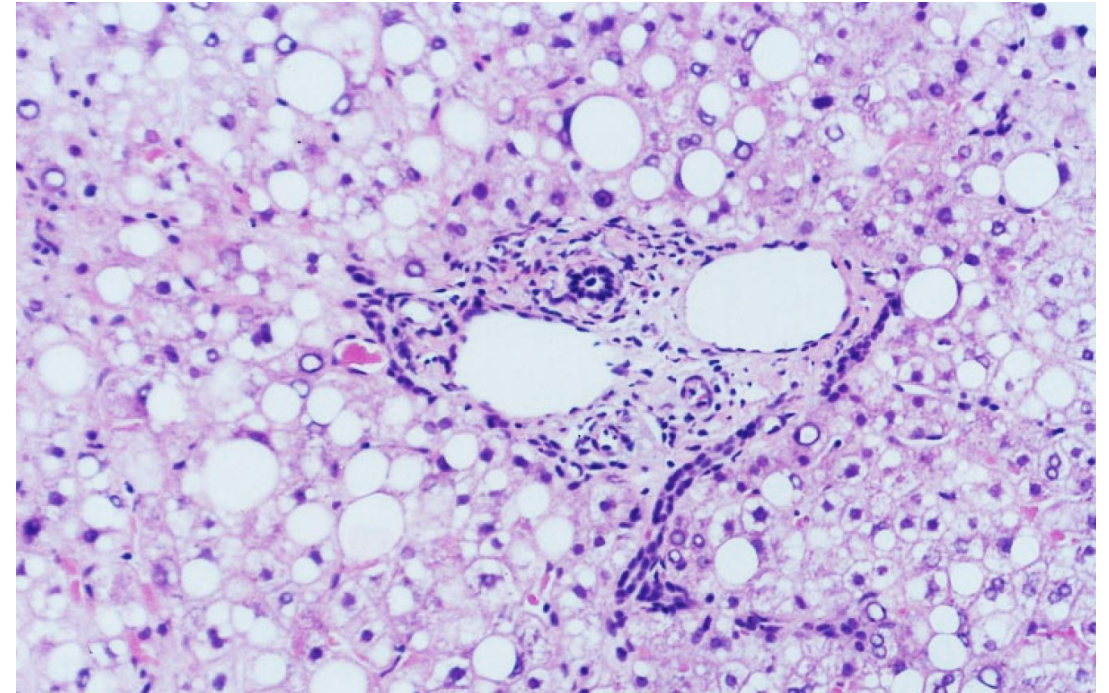
THE AMERICAN JOURNAL OF GASTROENTEROLOGY  
Vol. 94, No. 9, 1999

Elizabeth M. Brunt, M.D., Christine G. Janney, M.D., Adrian M. Di Bisceglie, M.D., Brent A. Neuschwander-Tetri, M.D., and Bruce R. Bacon, M.D.

*Department of Pathology and Division of Gastroenterology and Hepatology, Department of Medicine, Saint Louis University School of Medicine, St. Louis, Missouri*

**Table 1.** Necroinflammatory Grading System for Steatohepatitis

Mild, grade 1	Steatosis (predominantly macrovesicular) involving up to 66% of biopsy; may see occasional ballooned zone 3 hepatocytes; scattered intra-acinar pmn's ± intra-acinar lymphocytes; <u>no or mild portal chronic inflammation.</u>
Moderate, grade 2	Steatosis of any degree; ballooning of hepatocytes (predominantly zone 3) obvious; intra-acinar pmn's noted, may be associated with zone 3 pericellular fibrosis; <u>portal and intra-acinar chronic inflammation noted, mild to moderate.</u>
Severe, grade 3	Panacinar steatosis; ballooning and disarray obvious, predominantly in zone 3; intra-acinar inflammation noted as scattered pmn's, pms's associated with ballooned hepatocytes ± mild chronic inflammation; <u>portal chronic inflammation mild or moderate, not marked.</u>



Mild portal inflammation (Brunt et al, 1999)

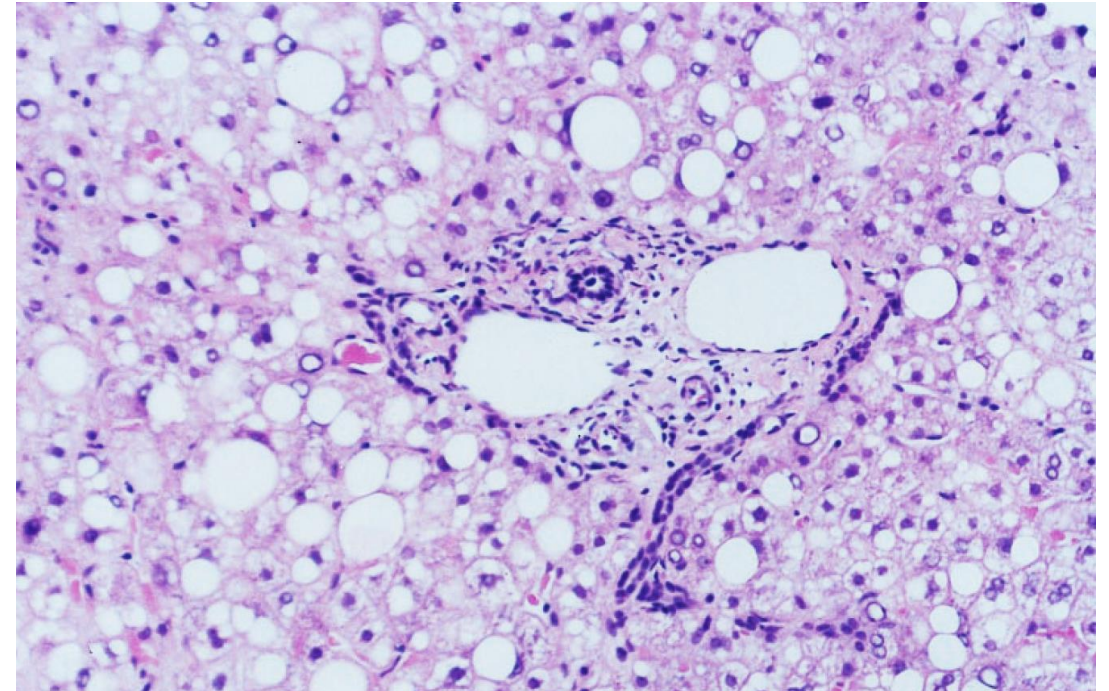
# Nonalcoholic Steatohepatitis: A Proposal for Grading and Staging the Histological Lesions

Elizabeth M. Brunt, M.D., Christine G. Janney, M.D., Adrian M. Di Bisceglie, M.D., Brent A. Neuschwander-Tetri, M.D., and Bruce R. Bacon, M.D.

*Department of Pathology and Division of Gastroenterology and Hepatology, Department of Medicine, Saint Louis University School of Medicine, St. Louis, Missouri*

**Table 1.** Necroinflammatory Grading System for Steatohepatitis

Mild, grade 1	Steatosis (predominantly macrovesicular) involving up to 66% of biopsy; may see occasional ballooned zone 3 hepatocytes; scattered intra-acinar pmn's ± intra-acinar lymphocytes; no or mild portal chronic inflammation.
Moderate, grade 2	Steatosis of any degree; ballooning of hepatocytes (predominantly zone 3) obvious; intra-acinar pmn's noted, may be associated with zone 3 pericellular fibrosis; portal and intra-acinar chronic inflammation noted, mild to moderate.
Severe, grade 3	Panacinar steatosis; ballooning and disarray obvious, predominantly in zone



**Table 2.** Results of Numerical Grading of NASH Biopsies

Grade	(n)	Steatosis*	Ballooning	Inflammation
1—Mild	22	1–2	Minimal	1–2 acinar; 0–1 portal
2—Moderate	23	2–3	Present—zone 3	2 acinar; 1–2 portal
3—Severe	6	3	Marked—zone 3	3 acinar; 1–2 portal

# Design and Validation of a Histological Scoring System for Nonalcoholic Fatty Liver Disease

HEPATOLOGY 2005 41:1313-1321

David E. Kleiner,<sup>1</sup> Elizabeth M. Brunt,<sup>2</sup> Mark Van Natta,<sup>3</sup> Cynthia Behling,<sup>4</sup> Melissa J. Contos,<sup>5</sup> Oscar W. Cummings,<sup>6</sup> Linda D. Ferrell,<sup>7</sup> Yao-Chang Liu,<sup>8</sup> Michael S. Torbenson,<sup>9</sup> Aynur Unalp-Arida,<sup>3</sup> Matthew Yeh,<sup>10</sup> Arthur J. McCullough,<sup>11</sup> and Arun J. Sanyal<sup>12</sup> for the Nonalcoholic Steatohepatitis Clinical Research Network<sup>13</sup>

## NAFLD biopsies

Study set: 576 adult, 162 paediatric

Validation set: 32 adult, 18 paediatric

Portal inflammation did not correlate with steatohepatitis

**Table 1. NASH Clinical Research Network Scoring System Definitions and Scores in Study Set**

Item	Definition	Score/Code	% Responses in Category for Study Set Cases	
			Adult (n = 576)	Pediatric (n = 162)
Portal inflammation	Assessed from low magnification			
	None to minimal	0	67%	67%
	Greater than minimal	1	33%	33%

**Table 2. Inter- and Intra-rater Variability**

Item	Agreement (Kappa Score)		
	Intra-rater	Interrater	
	Adult Cases (32 cases, 9 raters)	Adult Cases (32 cases, 9 raters)	Pediatric Cases (18 cases, 9 raters)
Steatosis, grade	0.83	0.79	0.64
Steatosis, location	0.39	0.31	0.39
Microvesicular steatosis	0.37	0.34	0.02
Fibrosis	0.85	0.84	0.62
Lobular inflammation	0.60	0.45	0.28
Microgranulomas	0.40	0.18	0.15
Lipogranulomas	0.38	0.26	0.00
Portal inflammation	0.55	0.45	0.42
Ballooning	0.66	0.56	0.22
Acidophil bodies	0.28	0.19	0.27
Pigmented macrophages	0.38	0.15	0.06
Megamitochondria	0.28	0.16	-0.03
Mallory's hyaline	0.64	0.58	0.69
Glycogenated nuclei	0.66	0.58	0.32
Diagnostic classification	0.66	0.61	0.32

Moderate inter-observer agreement  
for portal inflammation

NOTE. All values represent weighted kappa statistics where appropriate.

# Portal Chronic Inflammation in Nonalcoholic Fatty Liver Disease (NAFLD): A Histologic Marker of Advanced NAFLD—Clinicopathologic Correlations from the Nonalcoholic Steatohepatitis Clinical Research Network

Elizabeth M. Brunt,<sup>1</sup> David E. Kleiner,<sup>2</sup> Laura A. Wilson,<sup>3</sup> Aynur Unalp,<sup>3</sup> Cynthia E. Behling,<sup>4</sup> Joel E. Lavine,<sup>4</sup>

Brent A. Neuschwander-Tetri,<sup>5</sup> and the NASH Clinical Research Network<sup>6</sup> **HEPATOLOG** 2009 ;49:809-820

## Histological definition for portal inflammation in NAFLD

**None:** no inflammation or only rare inflammatory cells at high magnification in any portal area

**Mild:** a few mononuclear cells, usually, but not always, in more than one portal tract.

**More than mild:** at least one portal area showed a moderate to marked density of inflammation, and/or the presence of lymphoid aggregates

# Portal Chronic Inflammation in Nonalcoholic Fatty Liver Disease (NAFLD): A Histologic Marker of Advanced NAFLD—Clinicopathologic Correlations from the Nonalcoholic Steatohepatitis Clinical Research Network

Elizabeth M. Brunt,<sup>1</sup> David E. Kleiner,<sup>2</sup> Laura A. Wilson,<sup>3</sup> Aynur Unalp,<sup>3</sup> Cynthia E. Behling,<sup>4</sup> Joel E. Lavine,<sup>4</sup>

Brent A. Neuschwander-Tetri,<sup>5</sup> and the NASH Clinical Research Network<sup>6</sup> **HEPATOLOG** 2009 ;49:809-820

728 adult NAFLD biopsies

semiquantification of portal inflammation: none, mild, more than mild

## Portal inflammation correlated with

- increased age
- female gender
- higher BMI
- markers of insulin resistance
- severity of steatosis
- hepatocyte ballooning
- advanced fibrosis
- definite steatohepatitis

# Improvements in Histologic Features and Diagnosis Associated With Improvement in Fibrosis in Nonalcoholic Steatohepatitis: Results From the Nonalcoholic Steatohepatitis Clinical Research Network Treatment Trials

HEPATOLOGY, VOL. 70, NO. 2, 2019

Elizabeth M. Brunt,<sup>1</sup> David E. Kleiner,<sup>2</sup> Laura A. Wilson,<sup>3</sup> Arun J. Sanyal,<sup>4</sup> and Brent A. Neuschwander-Tetri<sup>5</sup> for the Nonalcoholic Steatohepatitis Clinical Research Network

**Two adult NASH treatment trials: PIVENS**

Pioglitazone vs Vitamin E vs placebo 96 weeks

FLINT

Obeticholic acid vs placebo 72 weeks

**Baseline and final paired liver biopsies**

TABLE 1. Baseline Demographic, Clinical, Histological, and Genotypic Characteristics of Patients Included in the Study

	PIVENS (N = 221)			FLINT (N = 200)*		
	Improved Fibrosis (n = 85)	Not Improved Fibrosis (n = 136)	<i>P</i>	Improved Fibrosis (n = 57)	Not Improved Fibrosis (n = 143)	<i>P</i>
Demographics and clinical characteristics						
Female gender	55 (65%)	76 (56%)	0.21	36 (63%)	97 (68%)	0.62
Age at enrollment (years)	46.6 ± 11.1	47.1 ± 12.4	0.74	50.9 ± 11.2	51.2 ± 11.5	0.89
Hispanic ethnicity	9 (11%)	19 (14%)	0.54	8 (14%)	18 (13%)	0.82
Race: white versus other	71 (87%)	116 (89%)	0.66	44 (77%)	121 (85%)	0.22
Type 2 diabetes <sup>†</sup>	0 (0%)	0 (0%)	—	34 (60%)	73 (51%)	0.35
Metabolic syndrome	49 (58%)	90 (66%)	0.25	41 (72%)	104 (73%)	1.00
Liver enzymes						
ALT (U/L)	77.0 ± 40.0	84.6 ± 51.0	0.25	75.0 ± 42.2	84.6 ± 50.7	0.21
AST (U/L)	55.0 ± 29.6	56.1 ± 29.2	0.80	57.7 ± 36.0	60.7 ± 35.3	0.58
Biopsy length (mm)	19.6 ± 9.3	20.1 ± 9.4	0.67	19.8 ± 10.1	21.6 ± 9.0	0.22
Liver histology						
Portal inflammation	<b>79%</b>	<b>84%</b>	0.52	<b>89%</b>	<b>88%</b>	0.62
None	18 (21%)	22 (16%)		6 (11%)	18 (13%)	
Mild	49 (58%)	88 (65%)		35 (61%)	94 (66%)	
More than mild	18 (21%)	26 (19%)		16 (28%)	31 (22%)	
NAS	5.1 ± 1.6	4.8 ± 1.3	0.08	5.5 ± 1.4	5.3 ± 1.3	0.18
Fibrosis stage (scale 0-4)	1.8 ± 0.8	1.3 ± 1.1	<0.001	2.1 ± 0.9	1.7 ± 1.1	<0.01
Steatohepatitis			0.34			0.51
Not	6 (7%)	18 (13%)		3 (5%)	16 (11%)	
Borderline	14 (16%)	23 (17%)		6 (11%)	13 (9%)	
Definite	65 (76%)	95 (70%)		48 (84%)	114 (80%)	

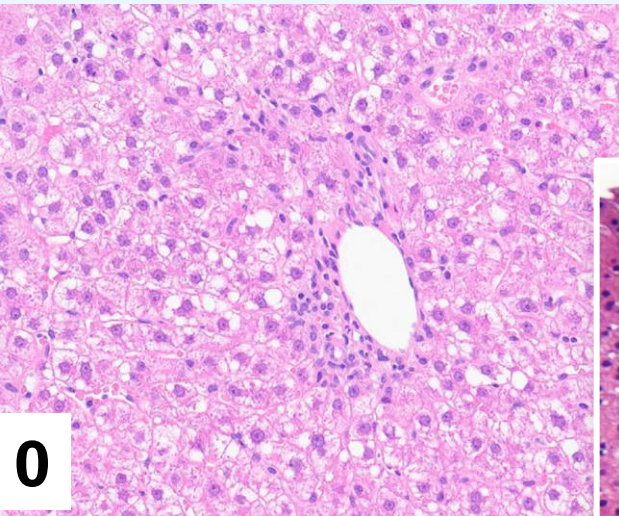
**TABLE 5. Logistic Regression Analysis of Fibrosis Improvement Versus No Fibrosis Improvement in PIVENS and FLINT Patients: Model Including Resolution of NASH and Improved NAS but not Components of the NAS**

Independent Discriminators for Fibrosis Improvement Versus No Improvement

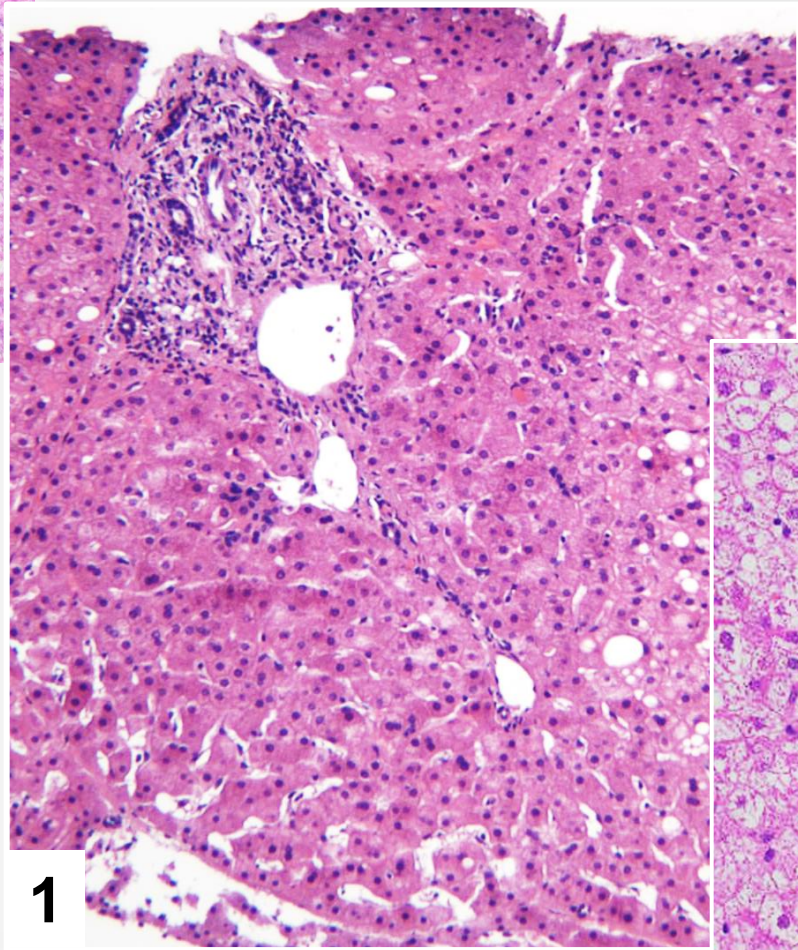
	PIVENS (N = 203)		FLINT (N = 190)	
	OR (95% CI)	<i>P</i>	OR (95% CI)	<i>P</i>
Resolution of steatohepatitis	4.1 (2.1-8.1)	<0.001	5.6 (2.0-15.6)	0.001
Improved NAS	n.s.		2.6 (1.2-5.7)	0.02
Improved portal inflammation	2.2 (0.9-5.2)	0.08	2.5 (0.9-7.0)	0.10
Improved Mallory-Denk bodies	2.6 (1.2-5.4)	0.01	2.1 (0.9-4.8)	0.08

**In NASH, improvement of portal inflammation from baseline strongly associated with fibrosis improvement in post-treatment liver biopsy**

# Semiquantification of portal inflammation in current NAFLD clinical trials

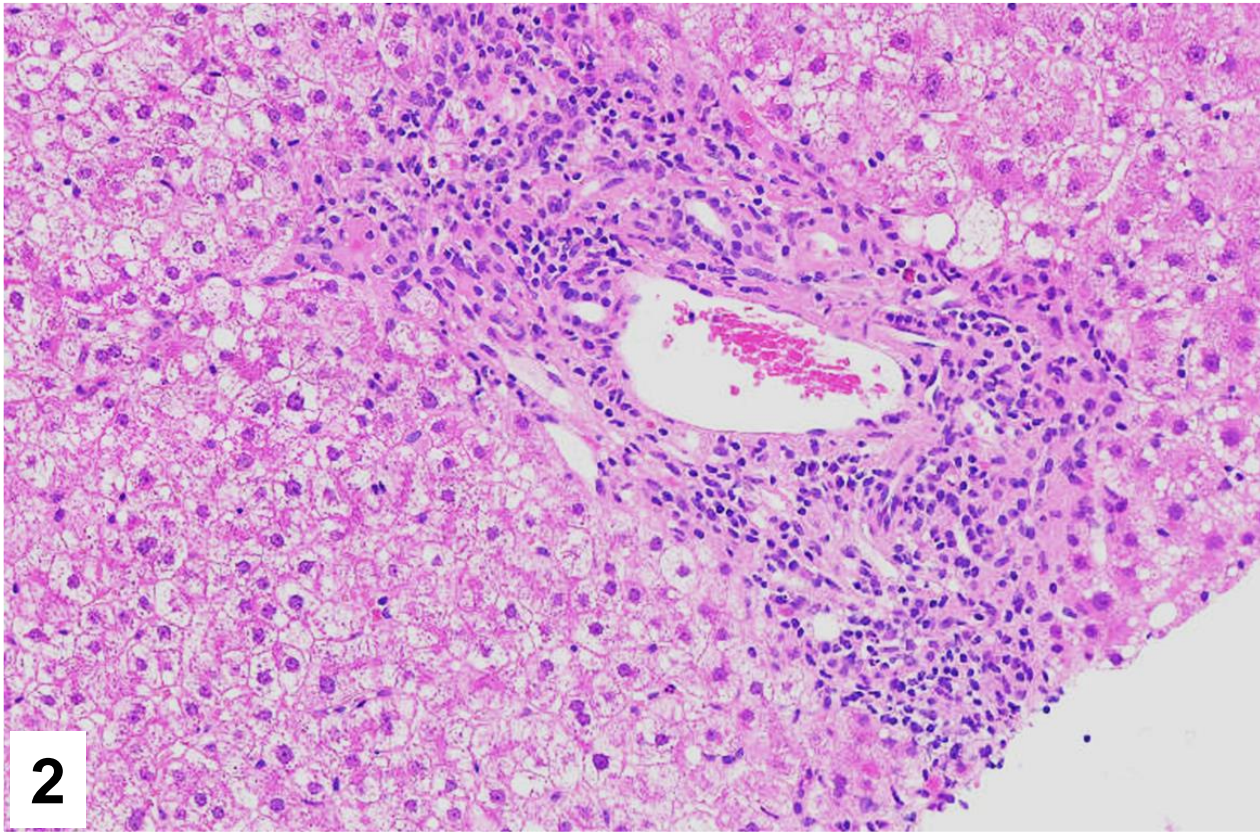


none

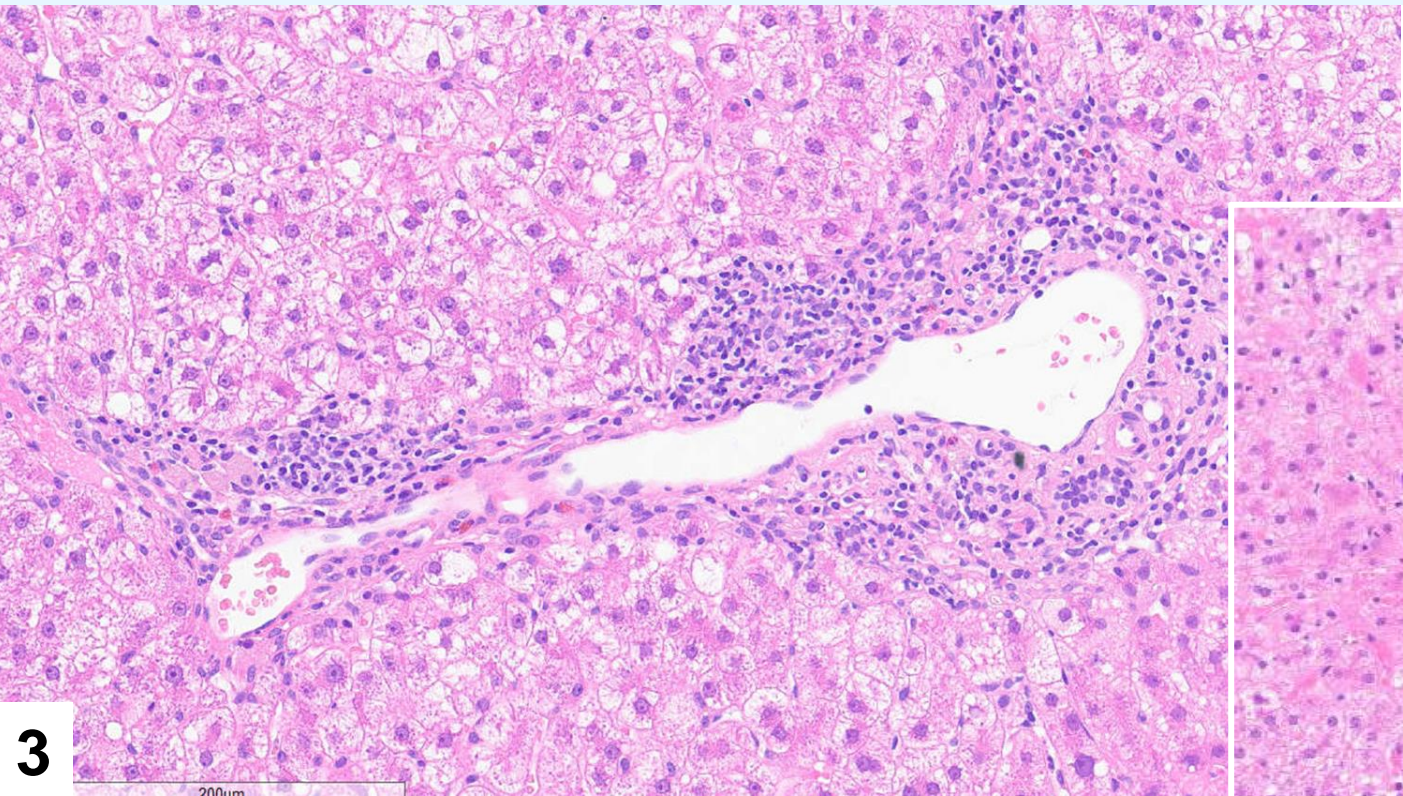


minimal: inflammation < matrix

mild: inflammation = matrix

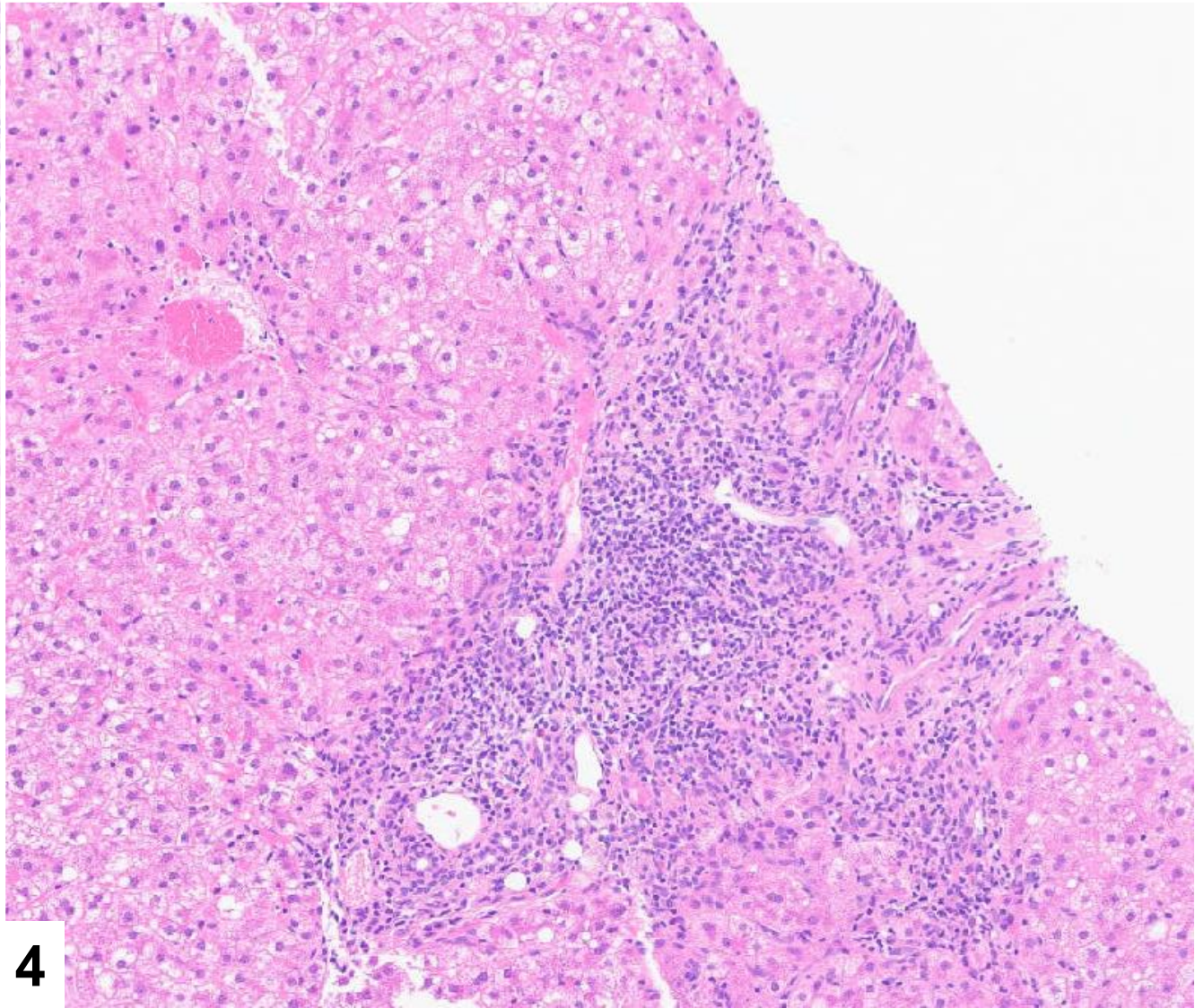


# Semiquantification of portal inflammation in current NAFLD clinical trials



3


**moderate:** inflammation > matrix



4

**severe:** inflammation > matrix, matrix expanded +/- interface activity

# NAFL/NASH concurrent with other liver disease

- **Frequent**  **high prevalence of insulin resistance and metabolic syndrome**
- Autoimmune hepatitis, CHC, CHB, biliary disease, HIV infection, inherited metabolic disease

*Kleiner & Brunt, Semin Liv Dis 2012  
Brunt, Mod Pathology 2003*

- In ALD, CHC and drug induced liver injury, development of steatosis or NASH may be independent of insulin resistance: *de novo* FLD or exacerbation of underlying NAFLD?
- **Concurrent NASH aggravates liver injury and accelerates fibrosis progression**

*Powell E, Dig Dis 2010*

# NAFL/NASH concurrent with other liver disease

- **Frequency of NASH concurrent with other chronic liver disease: 2.6%**

in a series of 3,581 nonallograft liver biopsies

- most common was CHC 5.5%
- autoimmune hepatitis 1.6%

*Brunt, Mod Pathology 2003*

- **Differential diagnosis is difficult:**

- steatosis, lobular inflammation, ballooning  
common in chronic hepatitis

**TABLE 1. Percentage of Biopsies with Steatohepatitis plus another Form of Chronic Liver Disease**

Chronic Liver Disease	No. of Biopsies, Total	No. of Biopsies with SH (%)
HCV (with and without alcohol)	1458	80 (5.5)
Primary biliary cirrhosis	81	5 (6.2)
$\alpha$ -1-AT deficiency	38	3 (7.9)
HFE (C282Y) mutation	44	1 (2.2)
HBV	59	2 (3.4)
Autoimmune	63	1 (1.6)
Drug-induced	42	1 (2.4)
Other Liver Diseases, total	327	13 (4.0)

# NAFL/NASH concurrent with other liver disease

- Frequency of NASH concurrent with other chronic liver disease: 2.6%

in a series of 3,581 nonallograft liver biopsies

- most common was CHC 5.5%
- autoimmune hepatitis 1.6%

*Brunt, Mod Pathology 2003*

- **Differential diagnosis is difficult:**

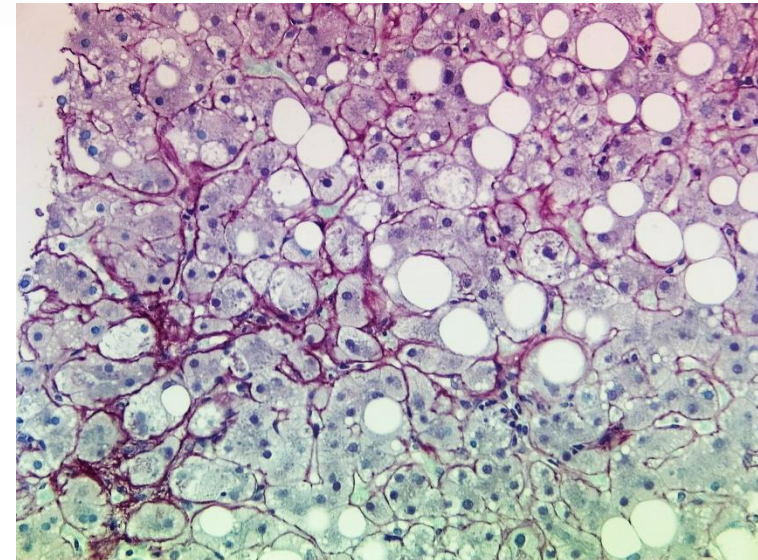
- steatosis, lobular inflammation, ballooning  
common in chronic hepatitis

- **Required for diagnosis of concurrent NASH:**

- Zone 3 sinusoidal/pericellular fibrosis
- Accentuation of necroinflammatory lesions in zone 3

**TABLE 1. Percentage of Biopsies with Steatohepatitis plus another Form of Chronic Liver Disease**

Chronic Liver Disease	No. of Biopsies, Total	No. of Biopsies with SH (%)
HCV (with and without alcohol)	1458	80 (5.5)
Primary biliary cirrhosis	81	5 (6.2)
$\alpha$ -1-AT deficiency	38	3 (7.9)
HFE (C282Y) mutation	44	1 (2.2)
HBV	59	2 (3.4)
Autoimmune	63	1 (1.6)
Drug-induced	42	1 (2.4)
Other Liver Diseases, total	327	13 (4.0)



## Common clinical problem:

# Positive autoantibodies in a patient with unexplained transaminasemia

- Up to 21% of NAFLD patients have positive autoantibody serology  
usually low titres ANA 21%, anti-SMA 5%, both ANA & anti-SMA 7%, AMA 2%

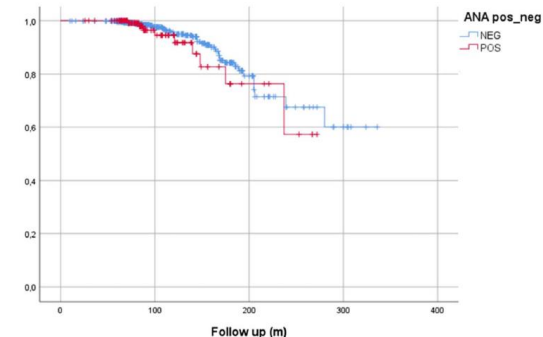
- + ↑  $\gamma$ -globulins in rare NAFLD patients

*Loria , Digg Dis 2003*

*Vuppalanchi, Hepatol Int 2012*

In a more recent study: *Younes, Am J Gastroenterol 2020*

- 16.9% of 923 biopsy-proven NAFLD patients with positive ANA (>1:40)
- ANA (+) NAFLD cases: higher prevalence of NASH, ballooning, F1-F3 fibrosis
- No patient developed AIH after long follow-up (106±50 months)
- ANA (+) patients similar outcome as ANA (-) NAFLD patients



## Common clinical problem:

# Positive autoantibodies in a patient with unexplained transaminasemia

## Non-alcoholic fatty liver disease/steatohepatitis (NAFLD/NASH)

- Up to 210% of NAFLD patients have **positive autoantibody serology** (usually low titres ANA, anti-SMA and/or AMA)

*Vuppalanchi, Hepatol Int 2012*

- + ↑ **γ-globulins**, in rare NAFLD patients

Using the clinical simplified scoring system for AIH,  
rare patients with NASH may be misdiagnosed as having probable AIH

# Diagnostic scoring systems for autoimmune hepatitis

## Simplified diagnostic criteria, 2008

	Variable	Cutoff	Points
◆	ANA or SMA	$\geq 1:40$	1
◆	ANA or SMA or LKM or SLA	$\geq 1:80$ $\geq 1:40$ Positive	2*
◆	IgG	$>$ Upper normal limit $> 1.10$ times upper normal limit	1 2
◆	Liver histology (evidence of hepatitis is a necessary condition)	Compatible with AIH Typical AIH	1 2
◆	Absence of viral hepatitis	Yes	2

$\geq 6$ : probable AIH  
 $\geq 7$ : definite AIH

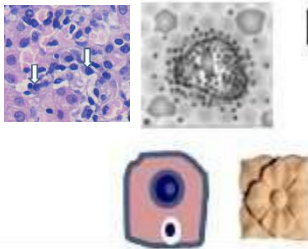
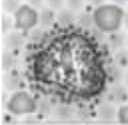
\*Addition of points achieved for all autoantibodies (maximum, 2 points).

**81-88% sensitivity, 97-99% specificity**

*Hennes EM et al, Hepatology 2008*

# Diagnostic scoring systems for autoimmune hepatitis

## Simplified diagnostic criteria, 2008

Variable	Cutoff	Points
<b>Histologic component of the simplified criteria for the diagnosis of AIH</b>		
Histologic Category	Description	Points
Typical	 <p>Includes interface hepatitis, lymphocytic or lymphoplasmacytic infiltrates in portal tracts extending into the lobule, emperipolesis, and hepatocyte rosette formation</p>	2
Compatible	 <p>Chronic hepatitis with lymphocytic infiltration without all the features considered typical</p>	1
Atypical	Includes evidence of another diagnosis	0

hepatitis

$\geq 6$ : probable AIH  
 $\geq 7$ : definite AIH

\*Addition of points achieved for all autoantibodies (maximum, 2 points).

*Hennes et al, Hepatology 2008*

## Case 1 history

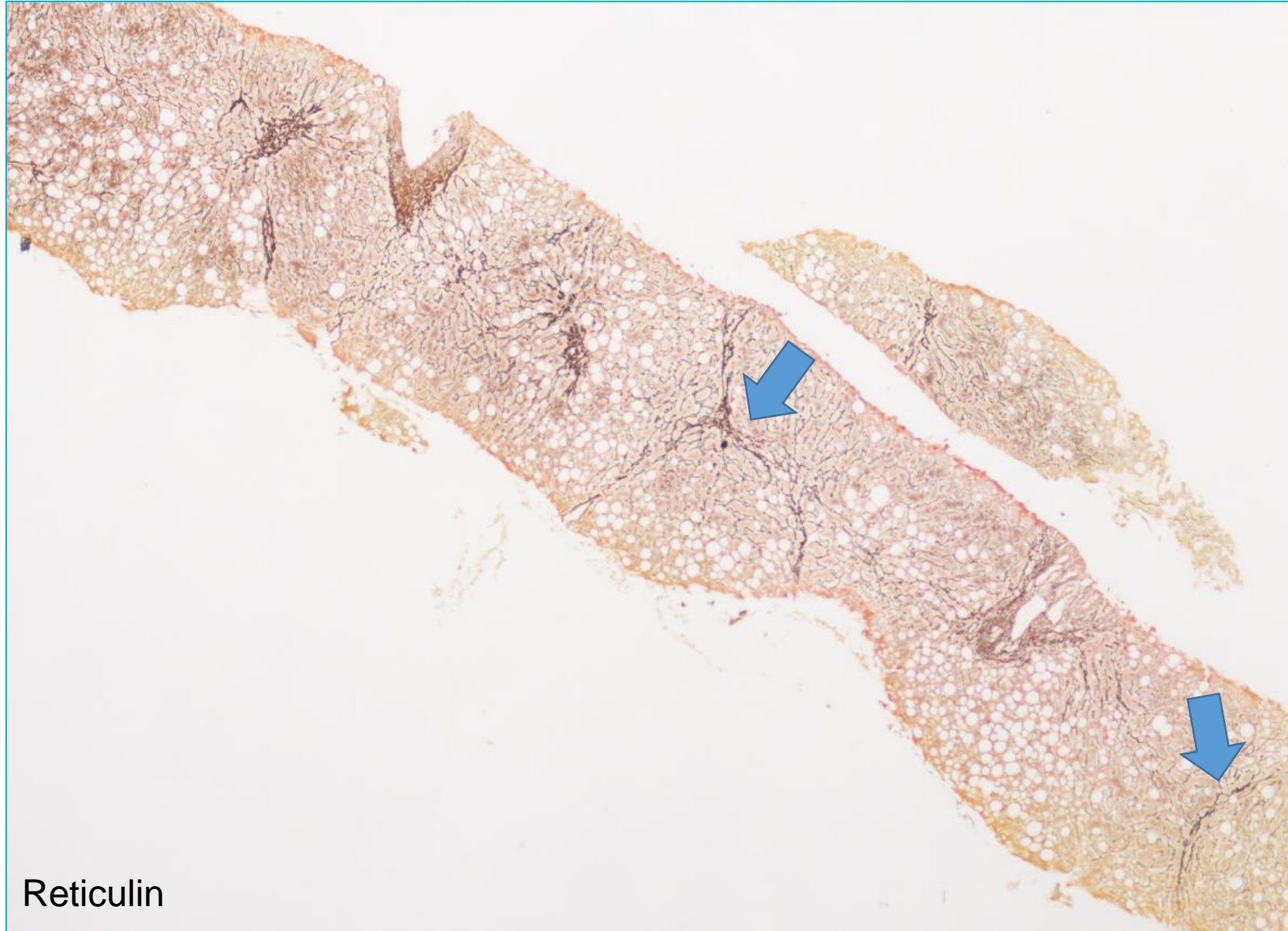
- 70 year old lady
- Referred from a local hospital for further management
- Presented with fatigue and found raised liver enzymes
- **ALT 164, AST 94**
- **ANA 1:80 and positive dsDNA and IgG 17.2 (ULN 15)**
- Otherwise asymptomatic, no history of autoimmune disease
- No medications or herbal remedies
- **Overweight with BMI 29.7**, dyslipidaemia, non-diabetic
- Alcohol 10 units/week, no previous history of alcohol excess
- No family history of liver disease

## Further history

- Referring clinician suspected AIH and empirically **treated with prednisolone 30mg for 6 weeks**
- No change in liver enzymes so this was stopped
- A liver biopsy was performed 4 weeks later

## Review of liver biopsy from local hospital

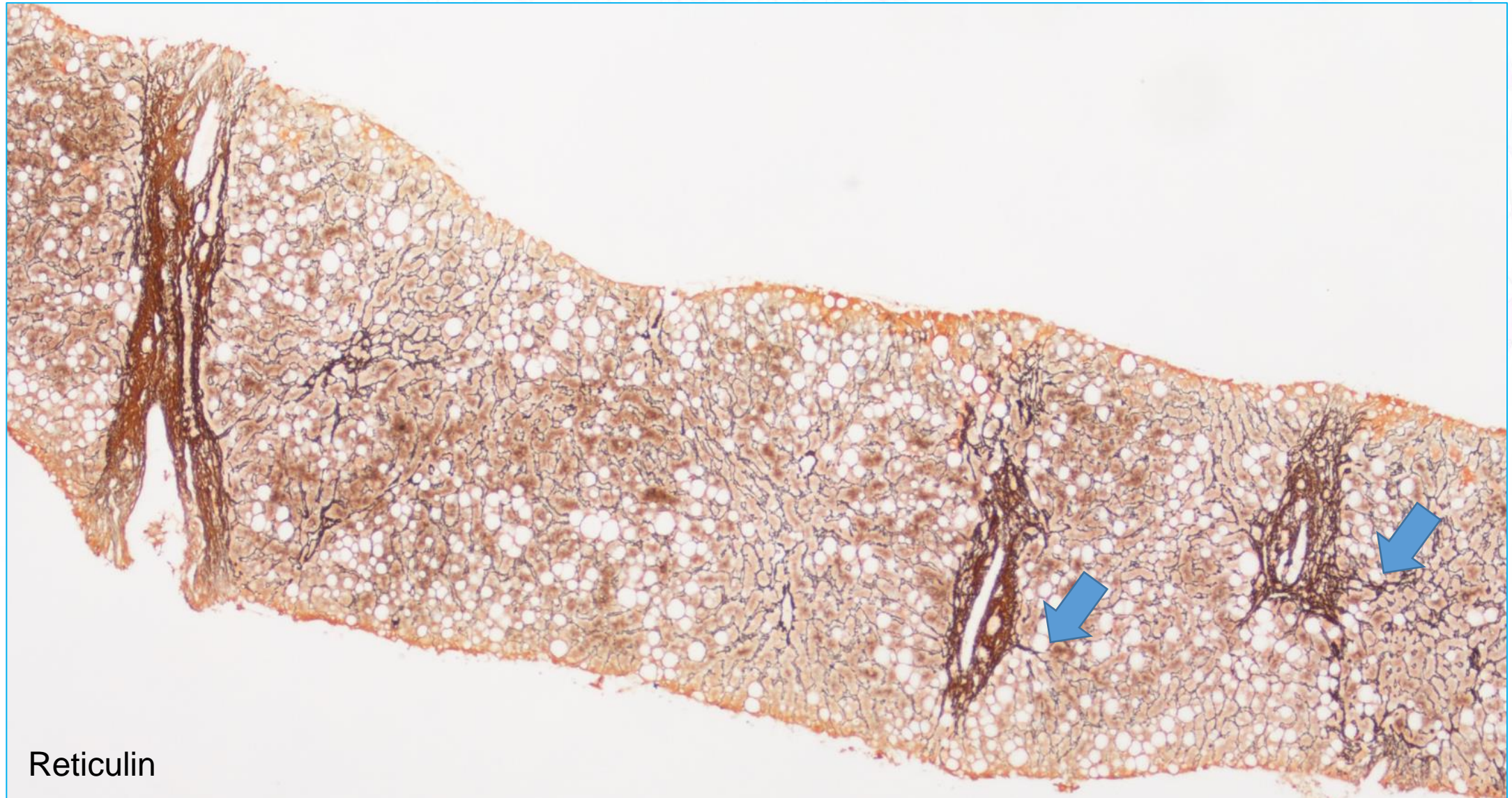
Good biopsy sample  
10 portal tracts



Case by Prof. A.D. Burt  
Photos by Dr Y. Bury,  
Royal Victoria Infirmary,  
Newcastle upon Tyne

Preserved architecture – Moderate steatosis – Thin fibrous septa

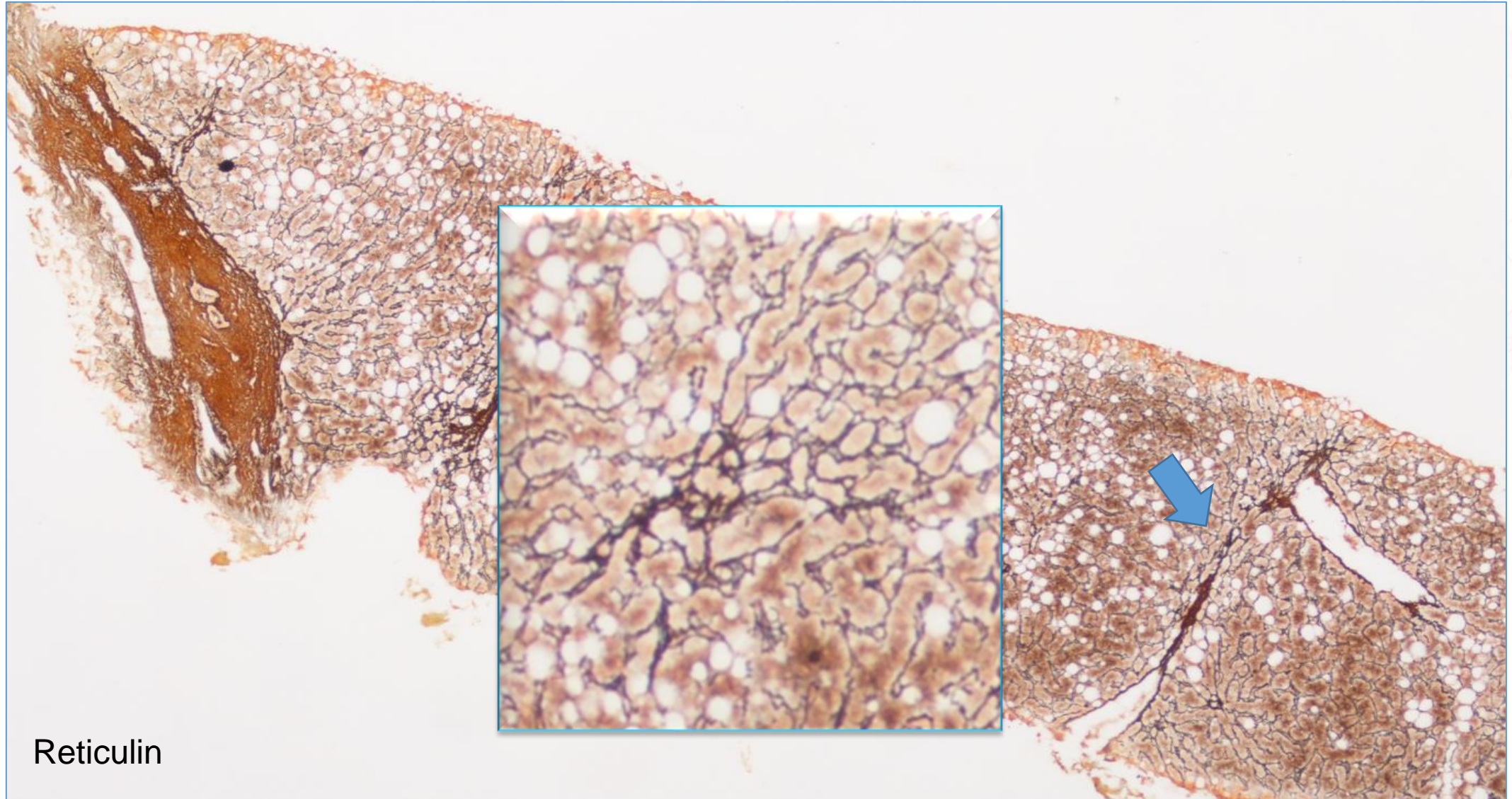
## Review of liver biopsy from local hospital



Reticulin

Periportal fibrosis with short fibrous septa

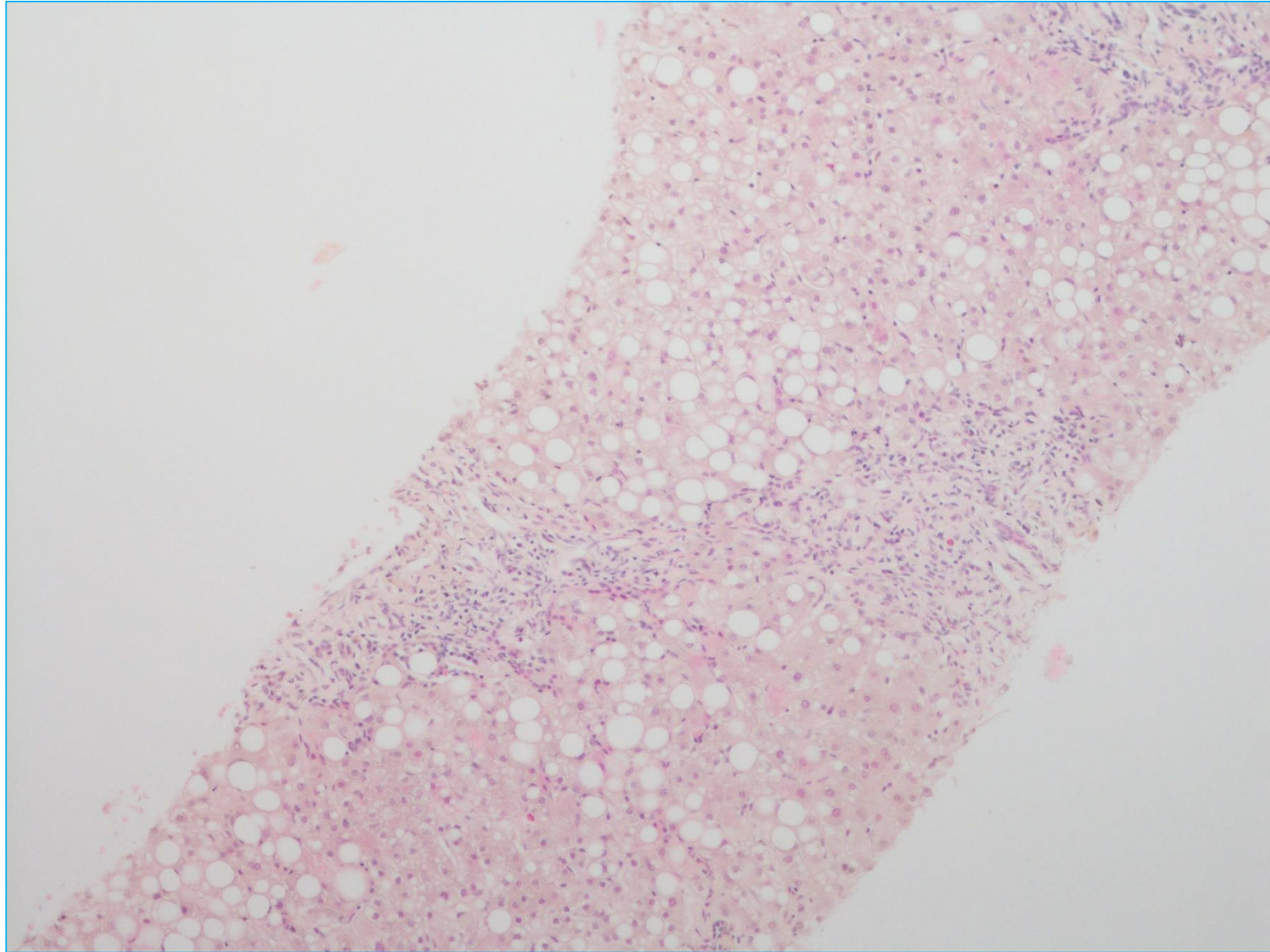
## Review of liver biopsy from local hospital



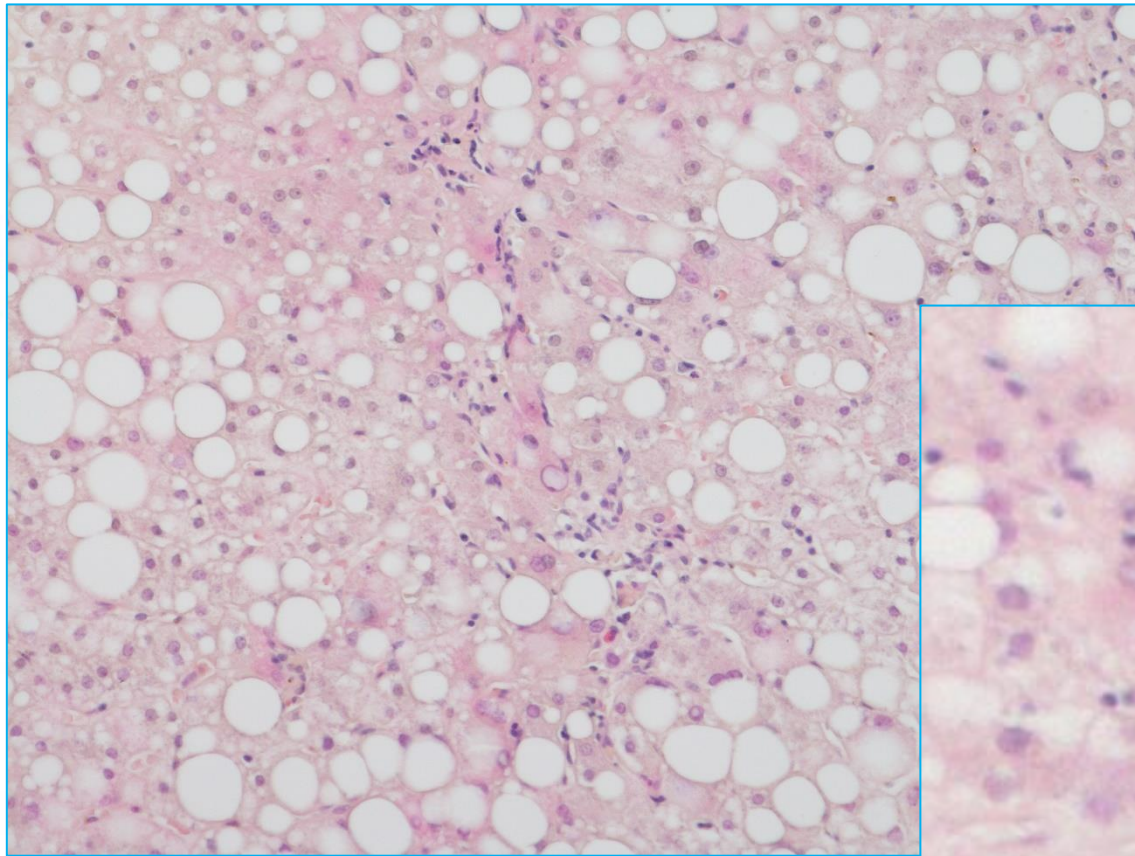
Reticulin

Perivenular fibrosis with pericellular distribution

## Review of liver biopsy from local hospital

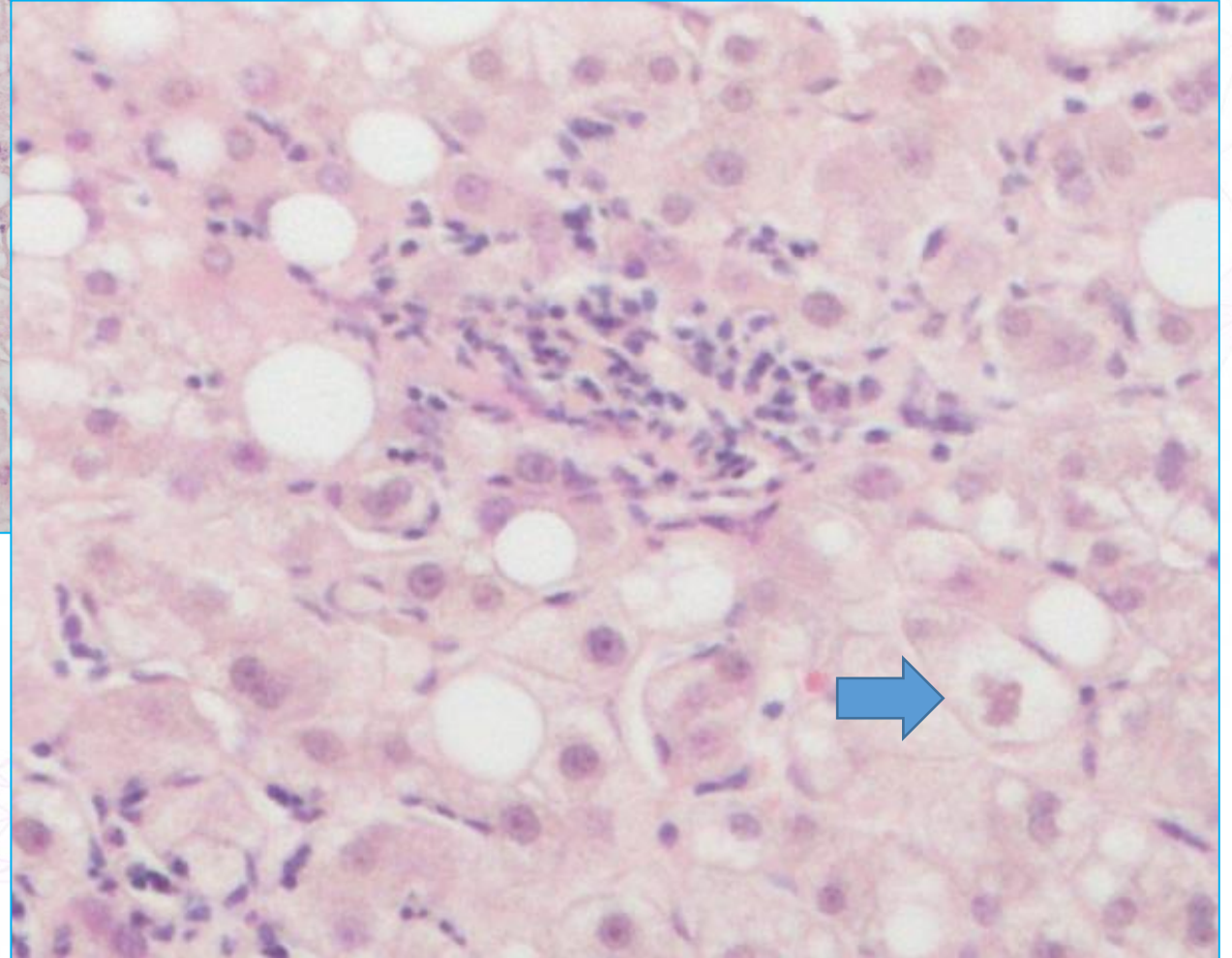


Moderate macrovesicular steatosis

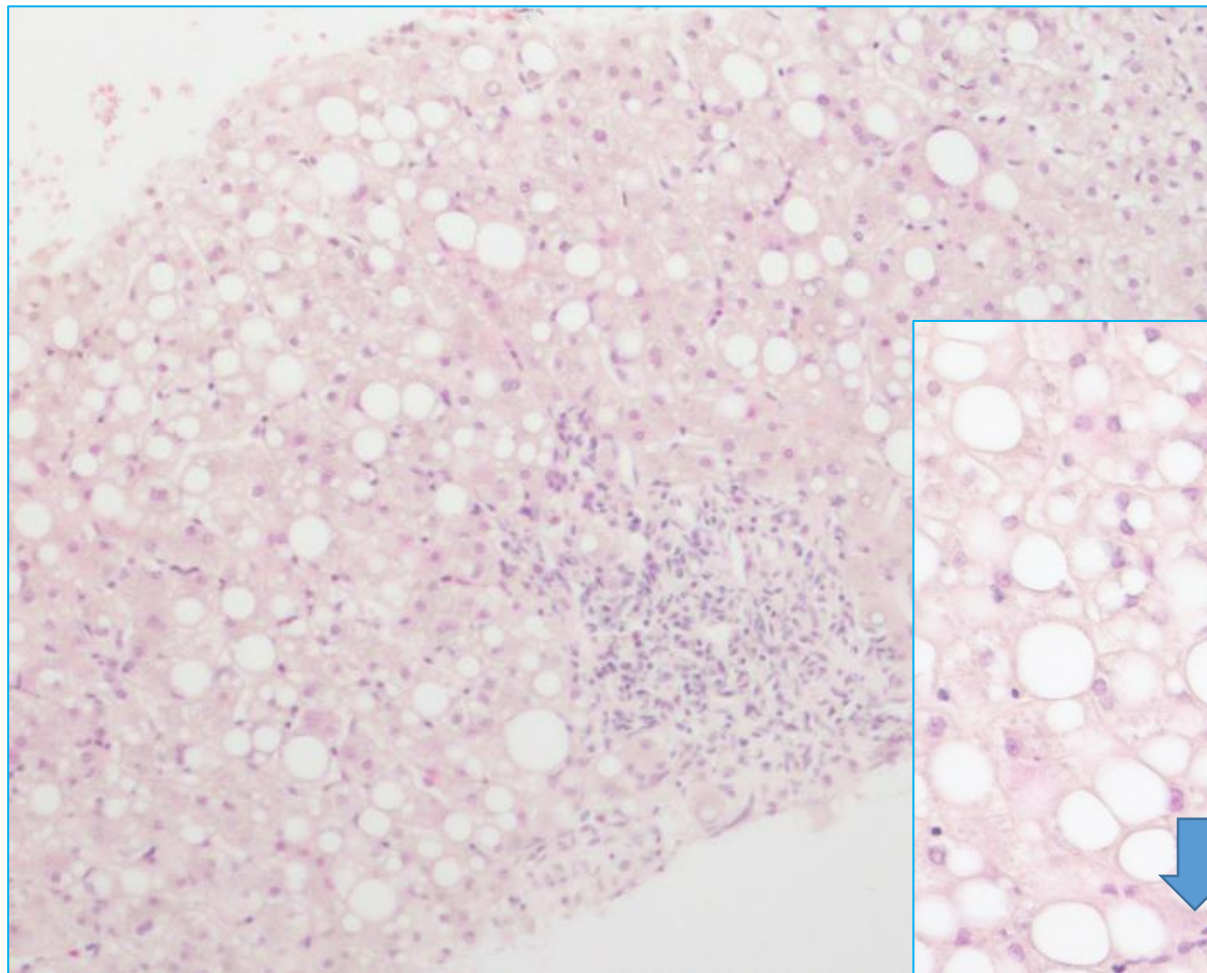


Lobular inflammation

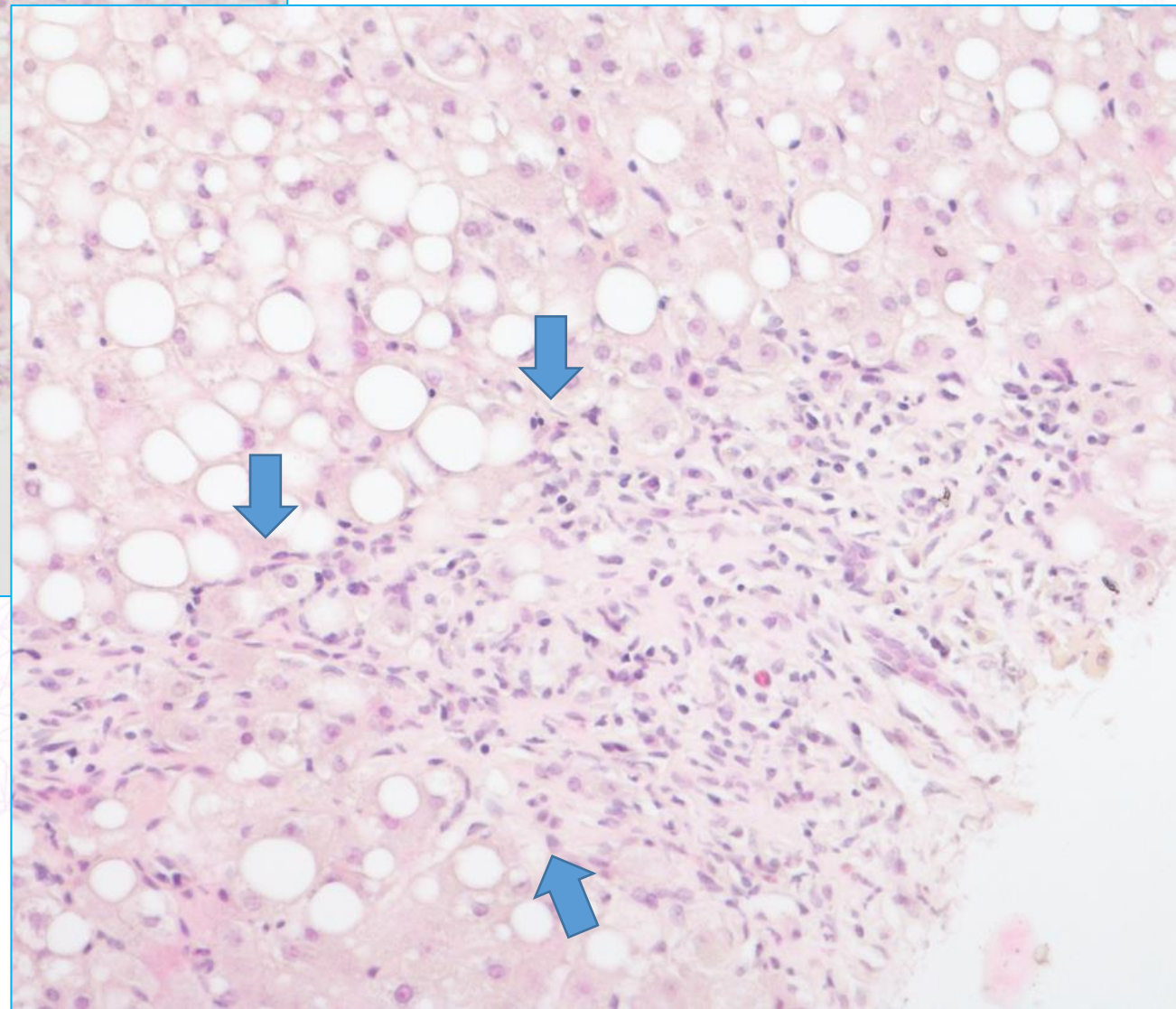
**Steatohepatitis with  
early bridging fibrosis**



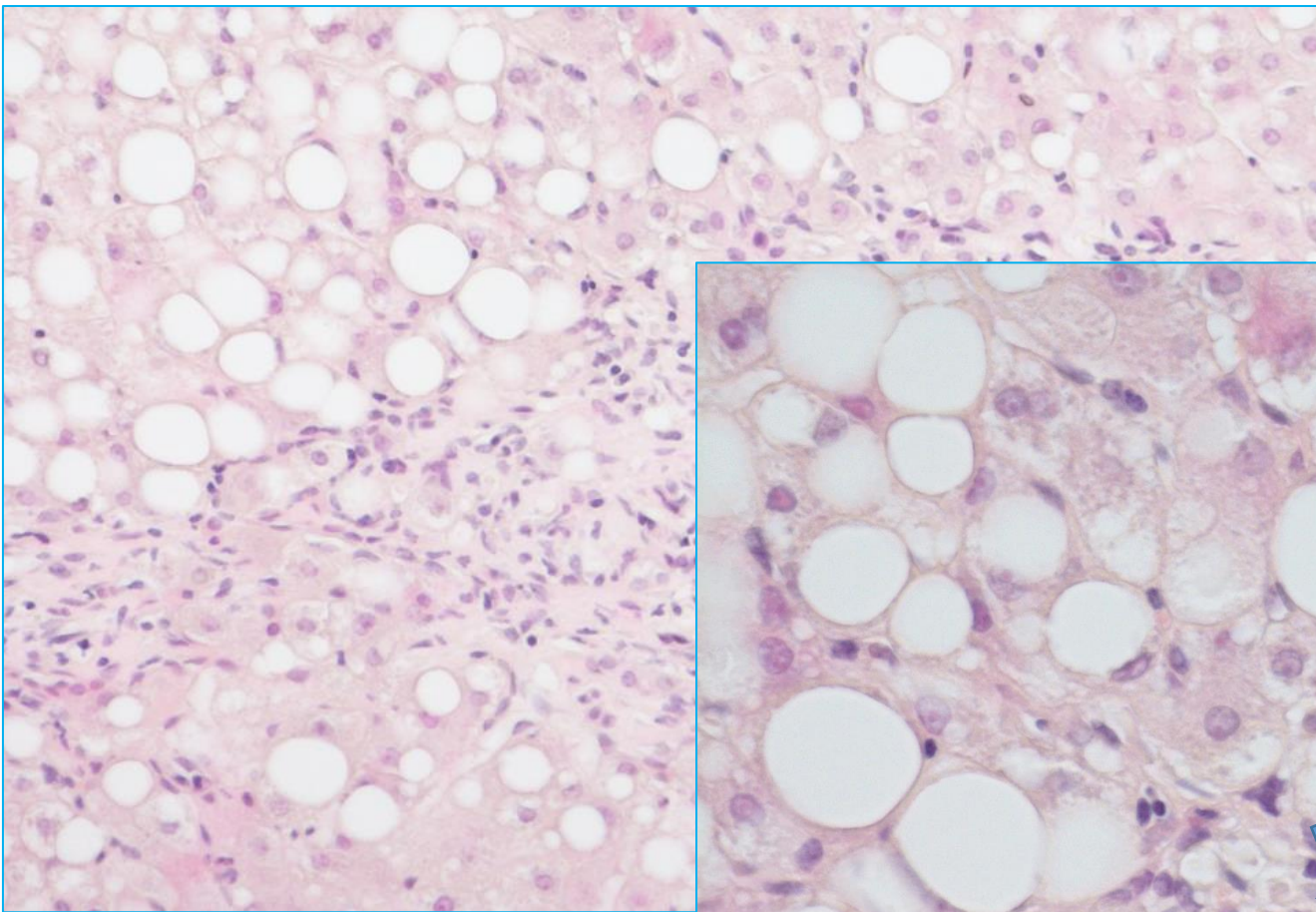
Occasional ballooning



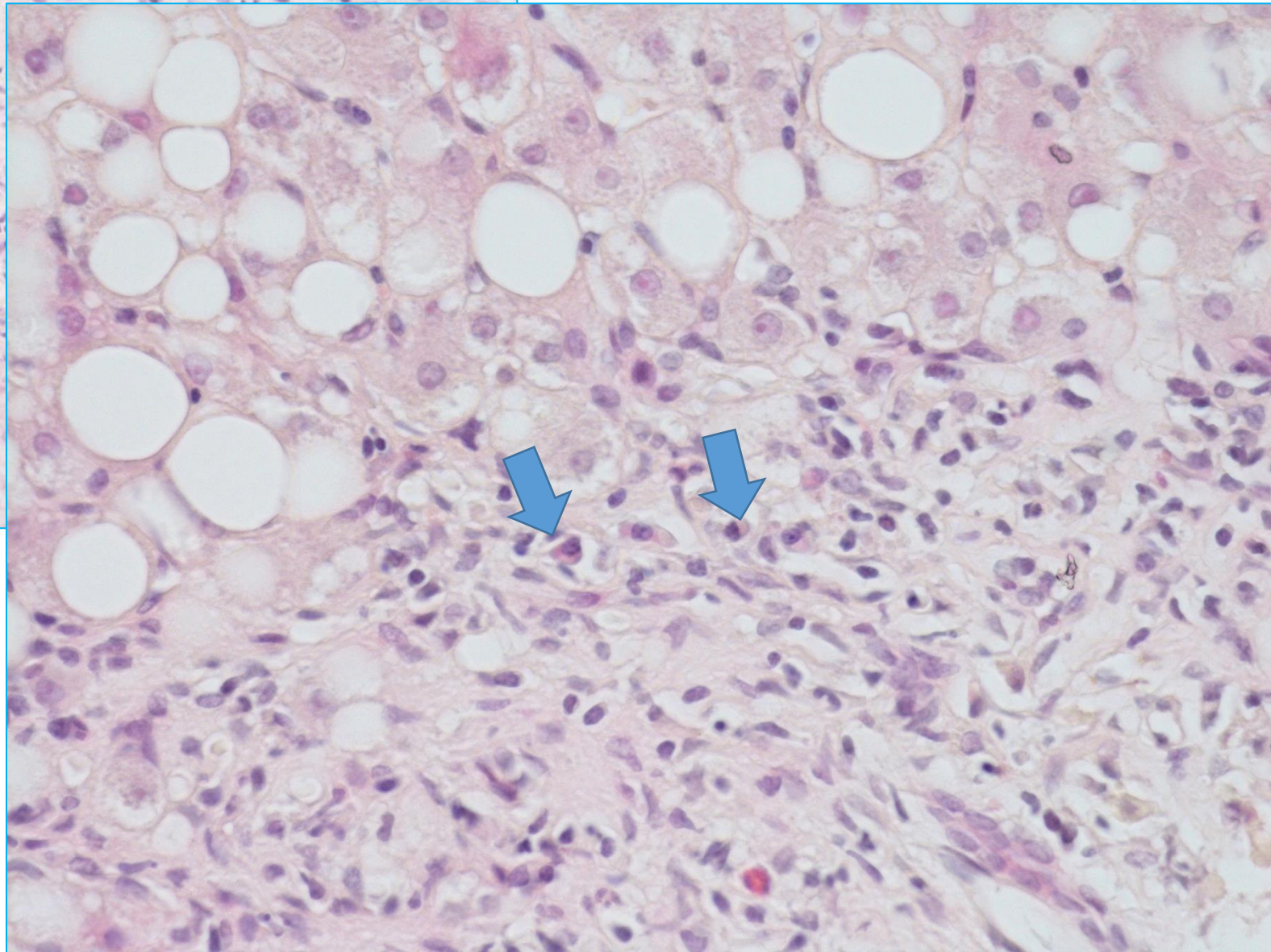
Moderate portal chronic inflammation



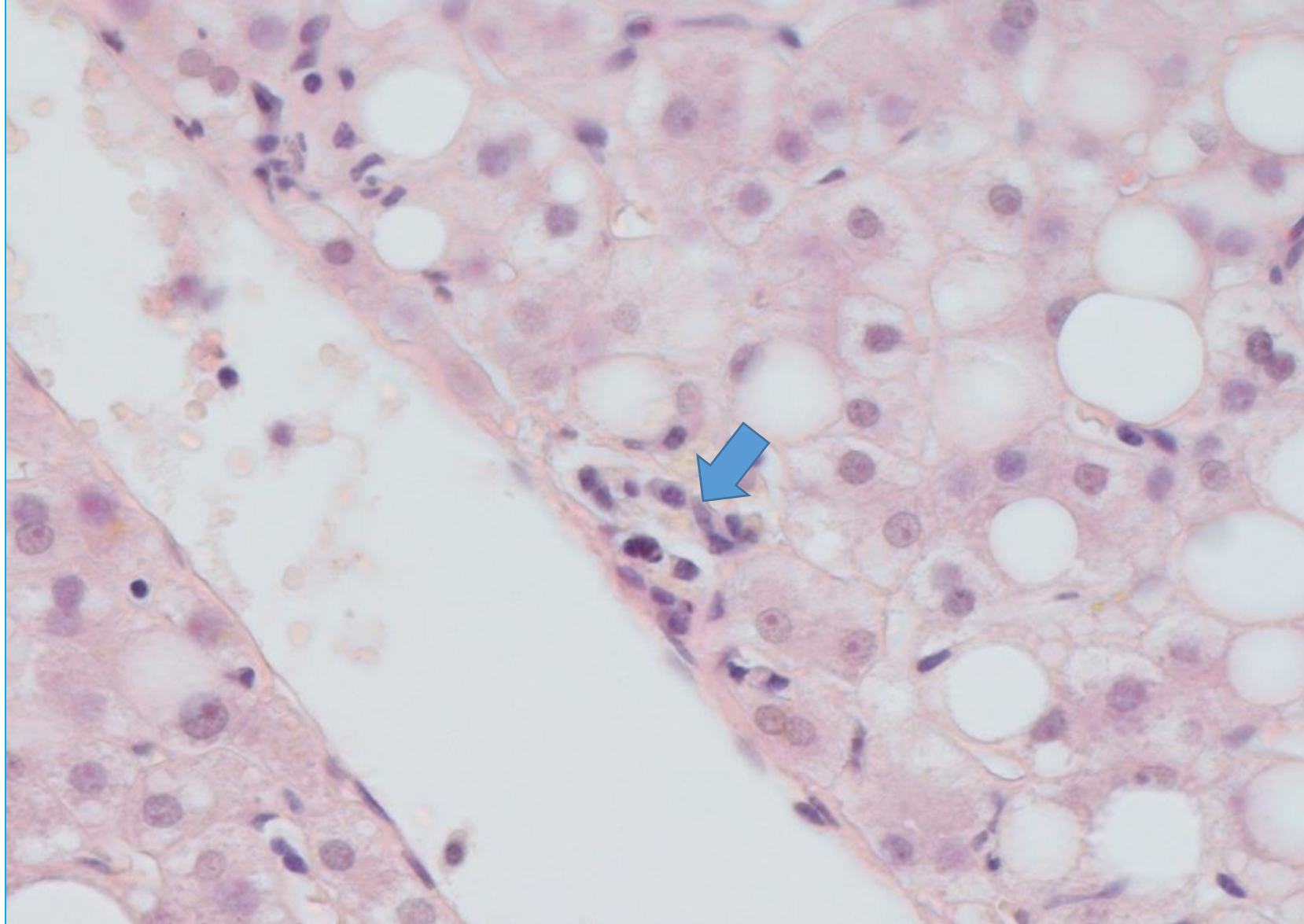
Focal interface activity



Portal interface activity



Plasmacytes in the  
chronic portal infiltrate



**Mild nonalcoholic steatohepatitis with early bridging fibrosis  
Suspicion of concurrent autoimmune hepatitis?**

Plasmacytes in perivenular inflammatory foci

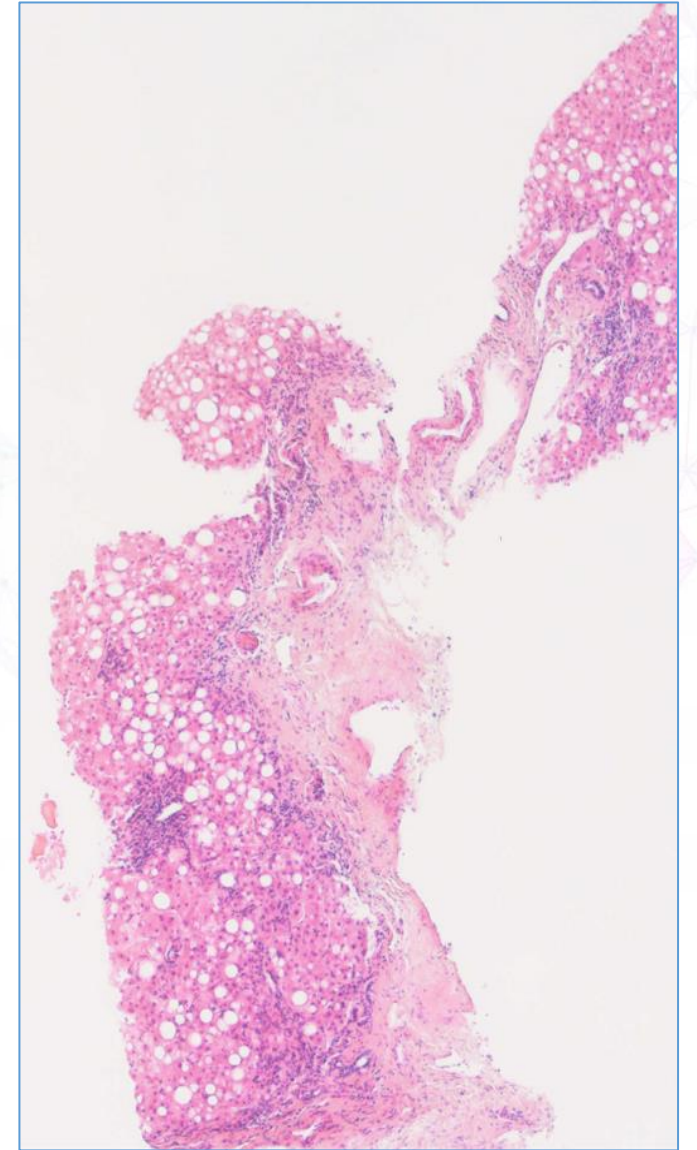
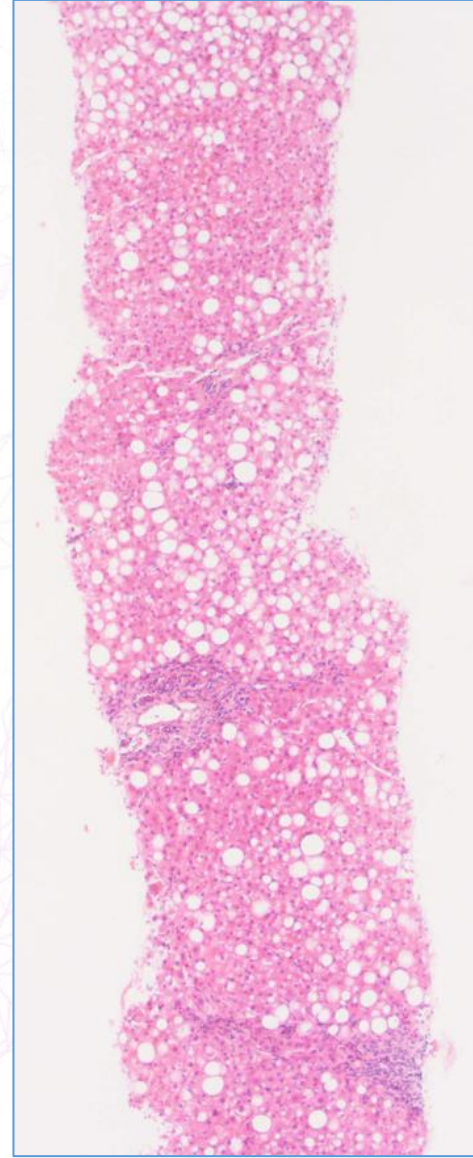
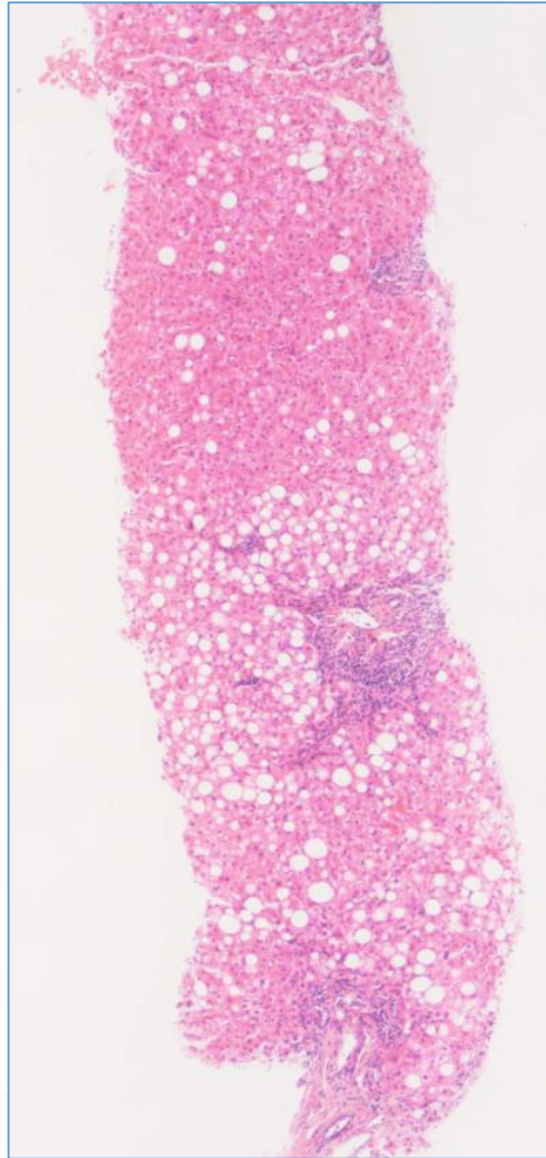
## Case 1 progress

- Coexistent autoimmune hepatitis that has in part been obscured by steroid therapy prior to biopsy?
- Repeat blood tests showed **ALT 190, ANA 1:320, IgG 17.9**
- A repeat liver biopsy was performed

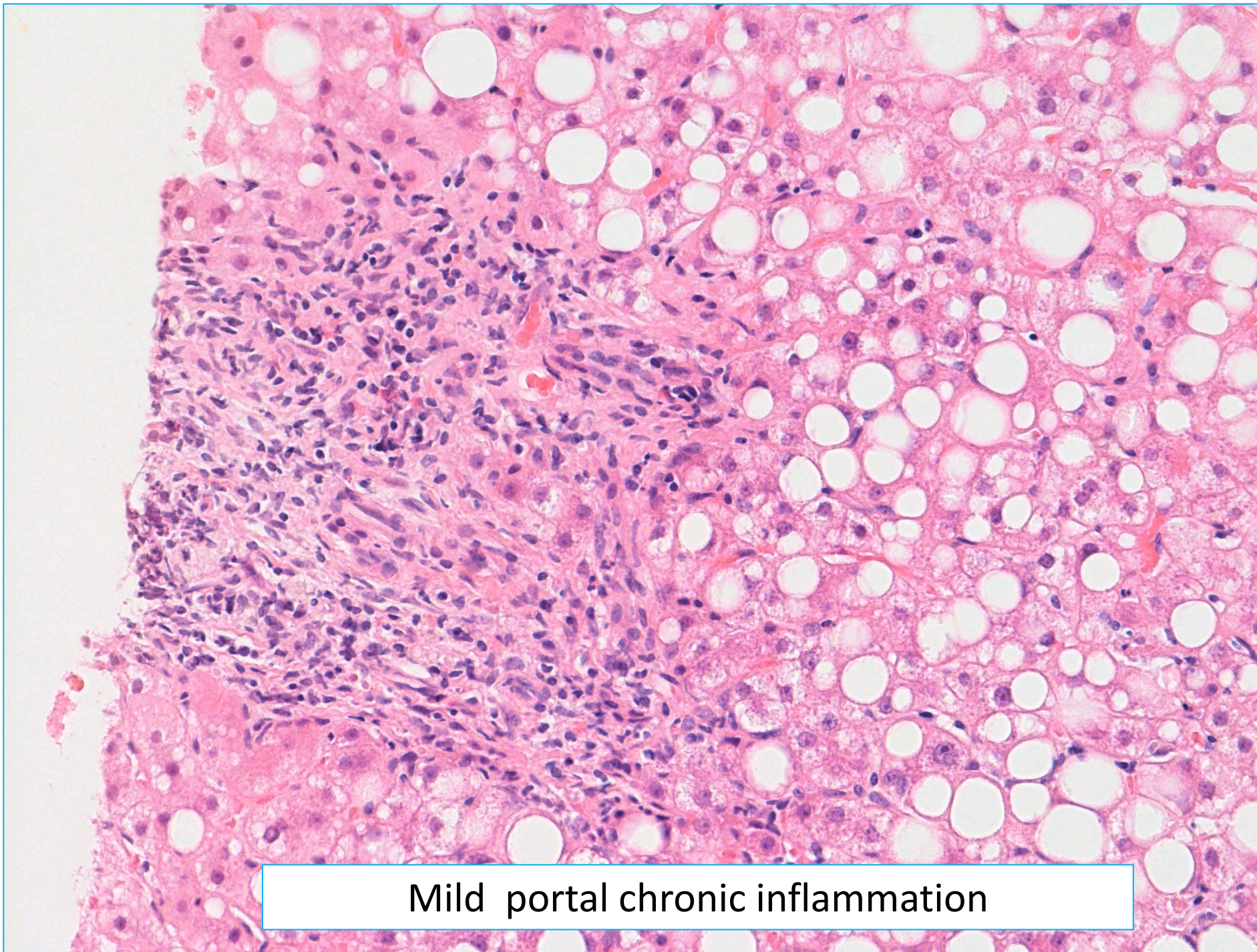
## 2<sup>nd</sup> Liver biopsy – 11 months after 1<sup>st</sup> biopsy

21 mm  
liver tissue core

Preserved architecture



Moderate macrovesicular steatosis


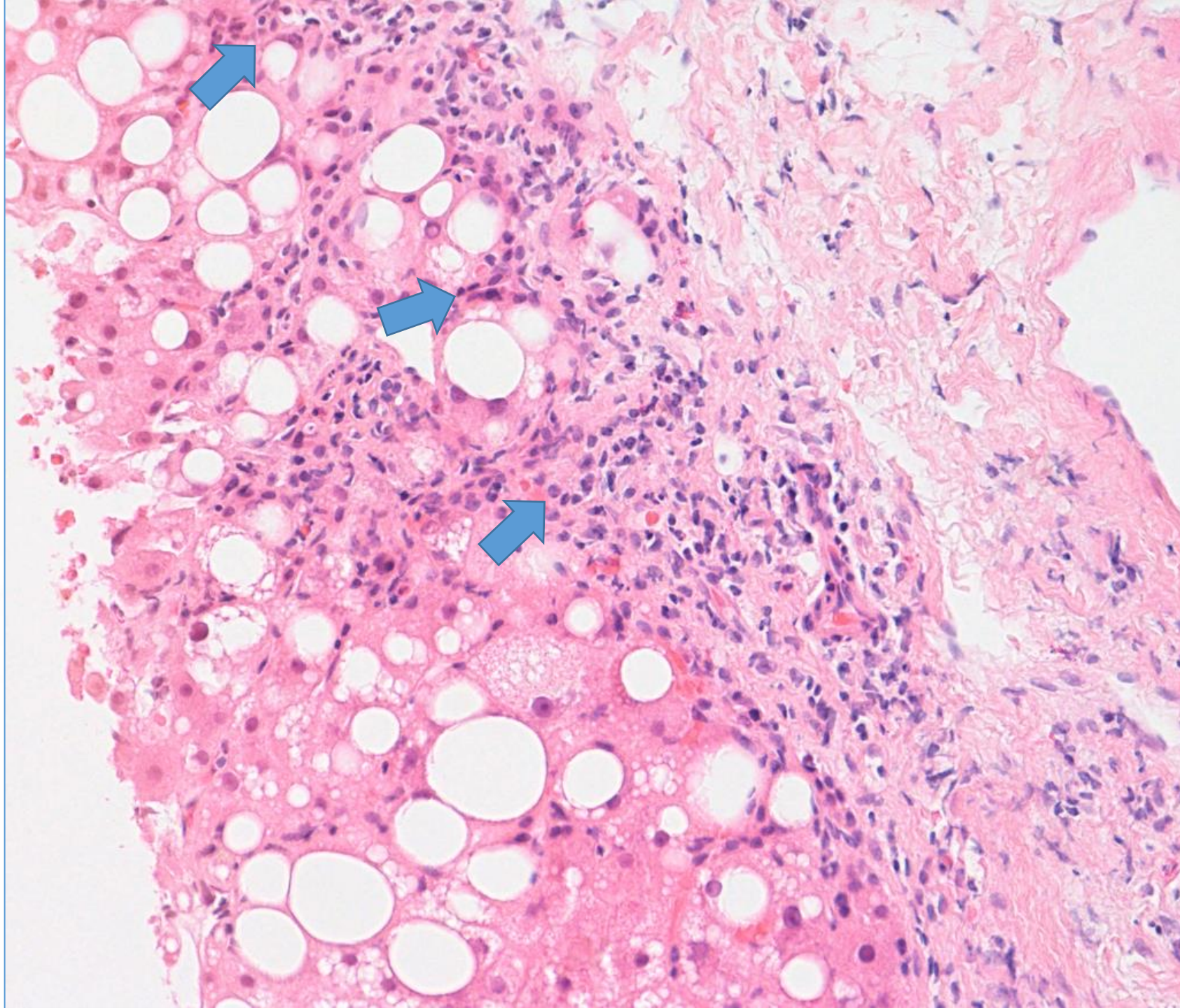


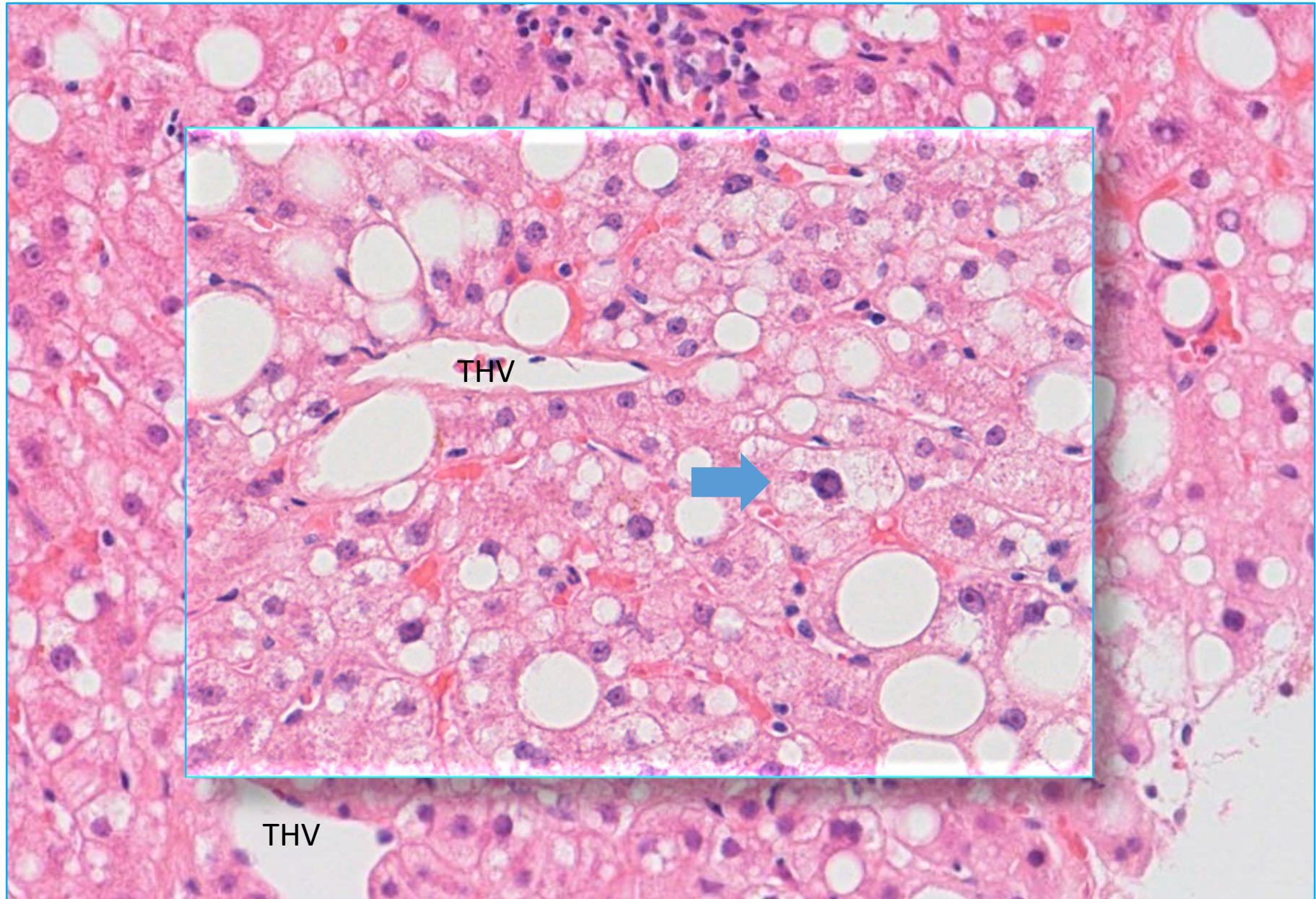
Mild portal chronic inflammation



Portal  
chronic  
inflammation

Focal interface  
activity

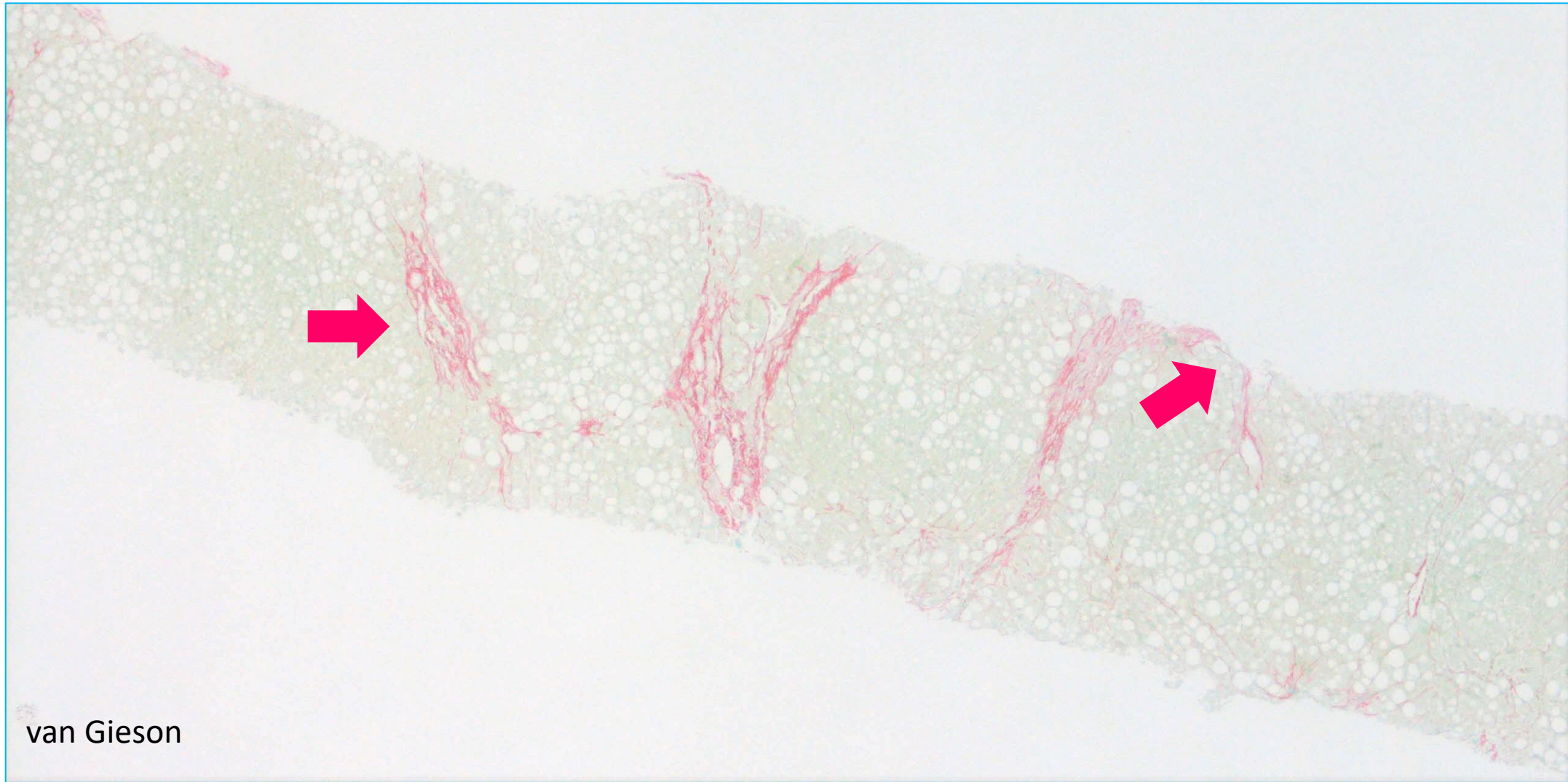




Mild lobular inflammation

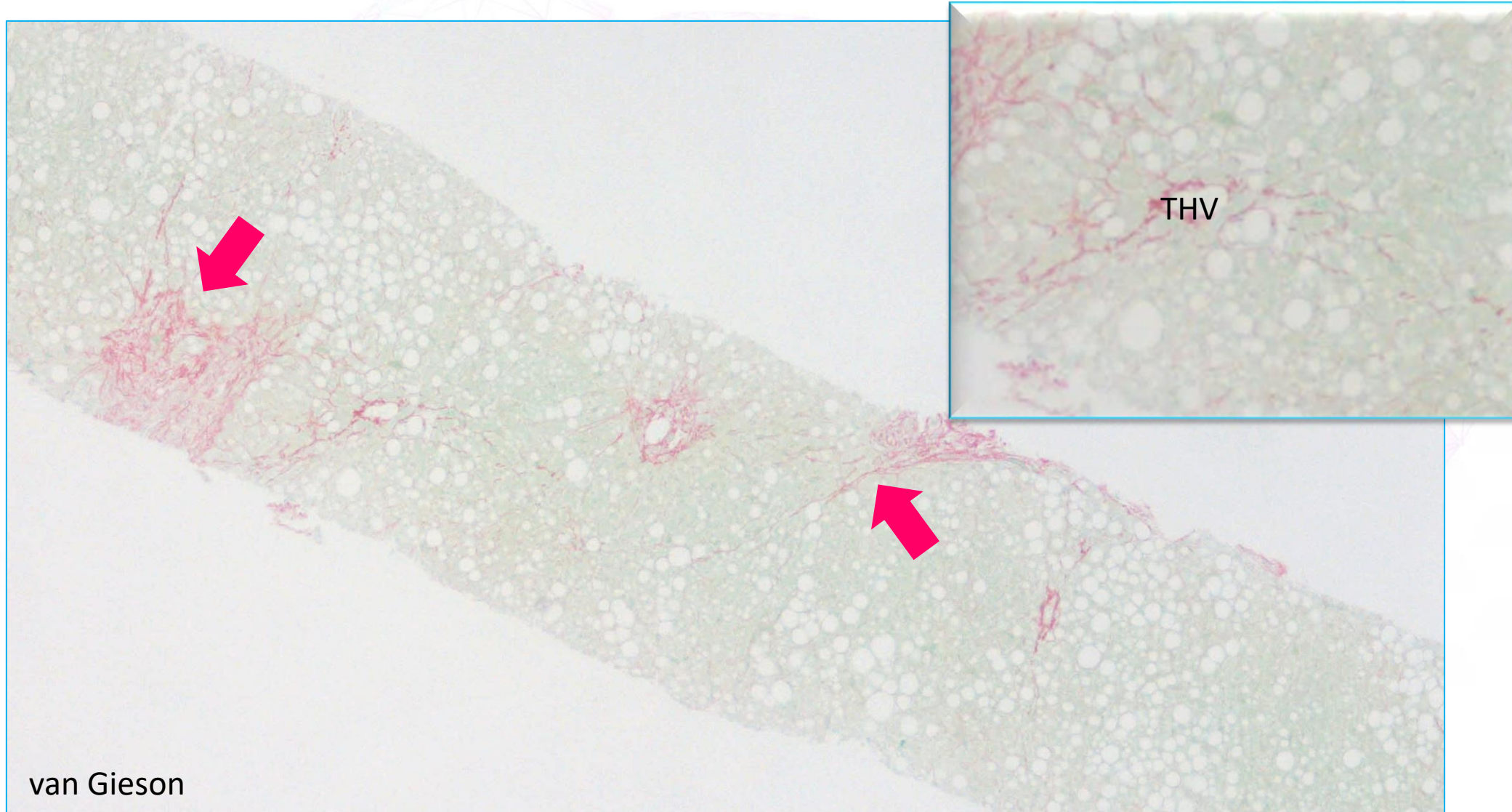
Occasional ballooning

## 2<sup>nd</sup> Liver biopsy – 11 months after 1<sup>st</sup> biopsy



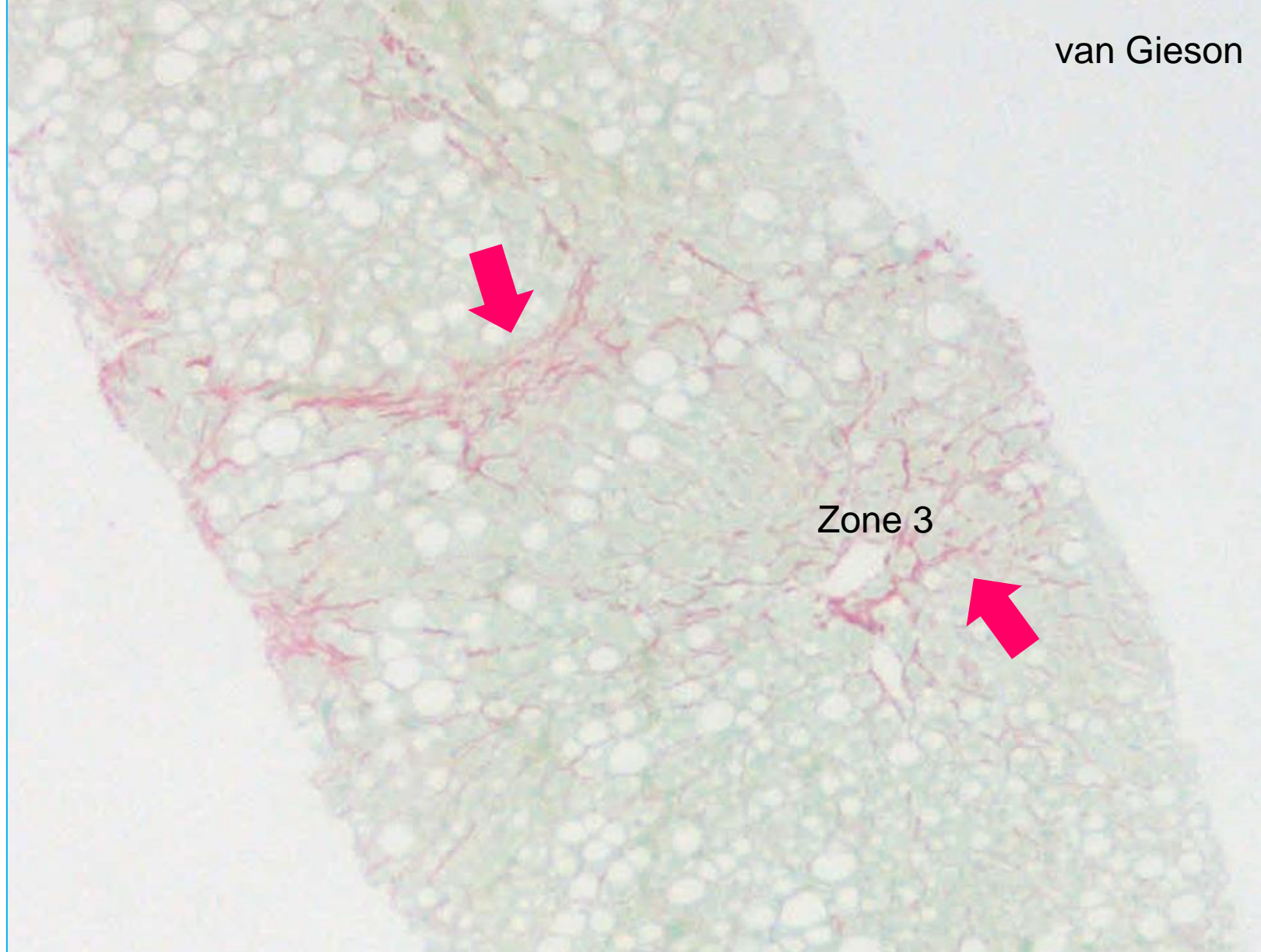
Portal/periportal fibrosis with short fibrous septa  
Early bridging fibrosis

## 2<sup>nd</sup> Liver biopsy – 11 months after 1<sup>st</sup> biopsy



Portal & periportal fibrosis with short fibrous septa

Zone 3 sinusoidal fibrosis



**Mild nonalcoholic steatohepatitis with early bridging fibrosis**  
[activity score NAS 4, fibrosis stage 3 (NASH CRN Kleiner et al 2005)]  
**Portal chronic inflammation part of the NASH spectrum?**

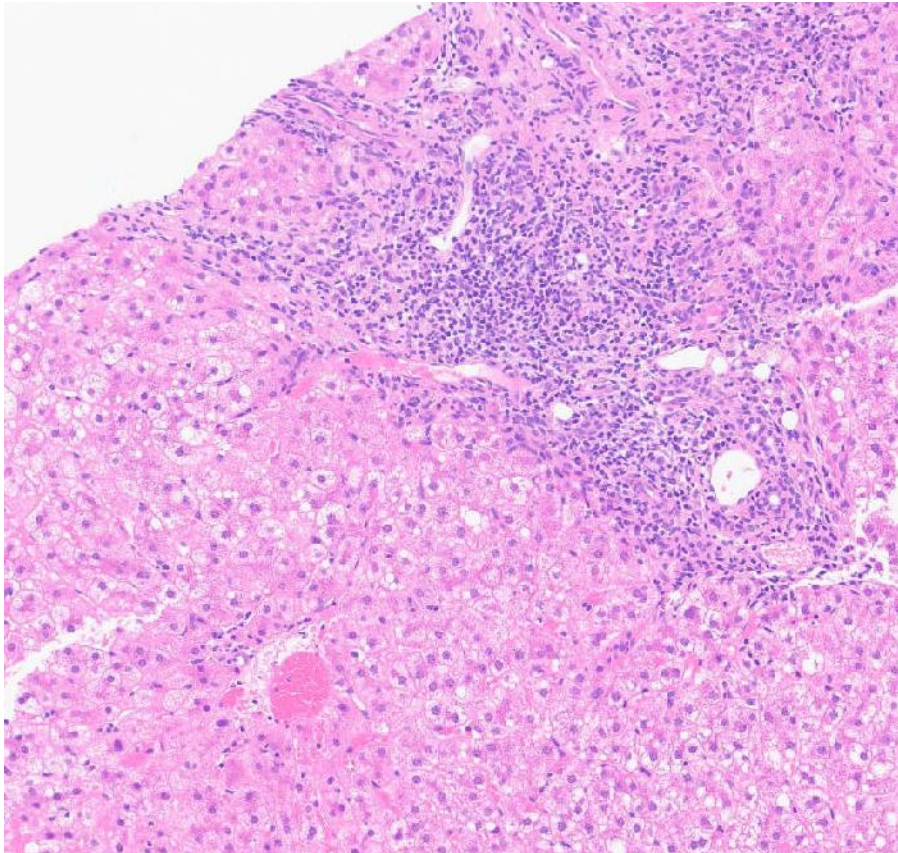
## Case 1 progress

- Repeat biopsy - NASH with no evidence of autoimmune hepatitis
- After 6 months she had lost 6% of bodyweight (BMI 28)
- ALT fell from 230 to 130
- Regained weight over the next 6 months (BMI 31.4 again)
- ALT 139 → Vitamin E 800 mg daily started
- ALT fell to 37 after 6 months on Vitamin E (weight stable)
- Vitamin E continued long term
- 3 years later Fibroscan reading was 7 kPa
- **10 years later she is well** and now aged 81 and Fibroscan remains 7 kPa

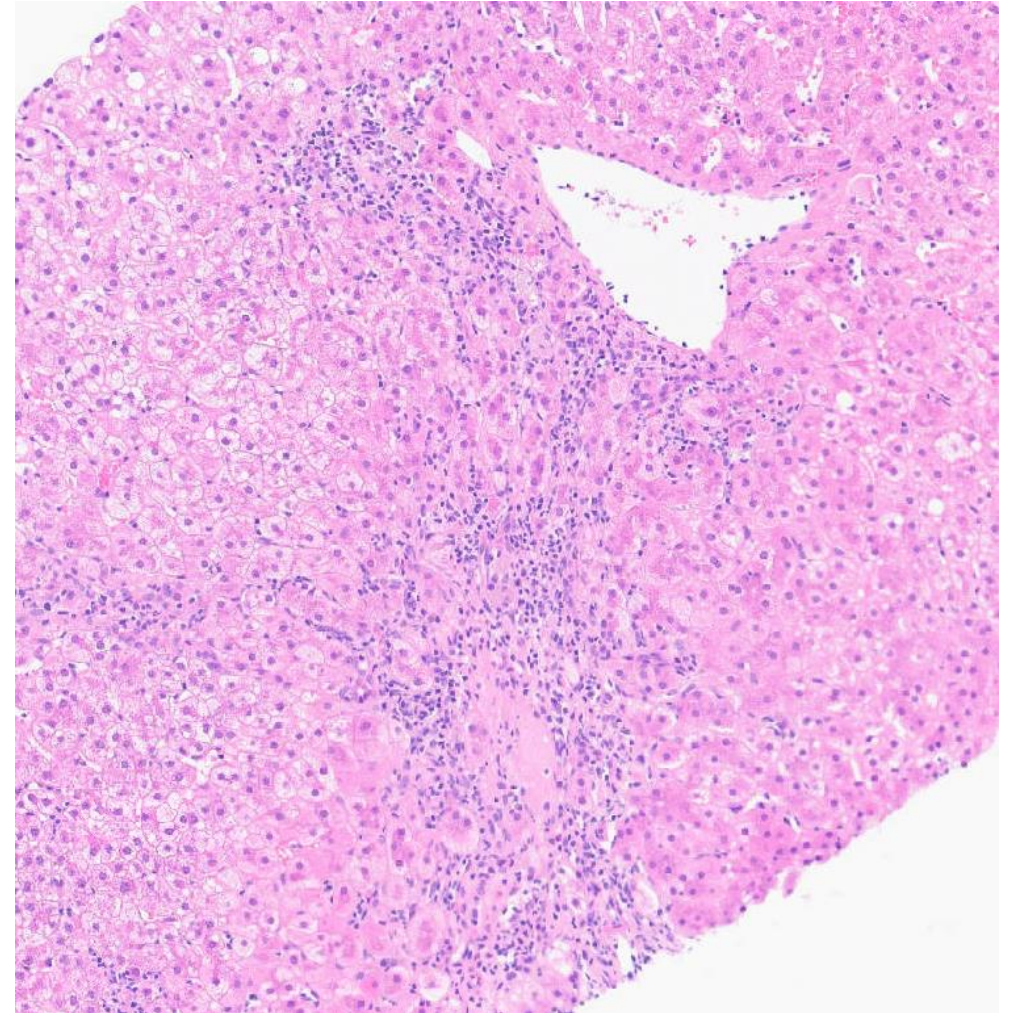
# Increased portal inflammation in NAFLD/NASH

## When to suspect a second pathology?

**Case 2:** Fatty liver. Increased Fibroscan values.  
Suspected NASH. No clinical info.

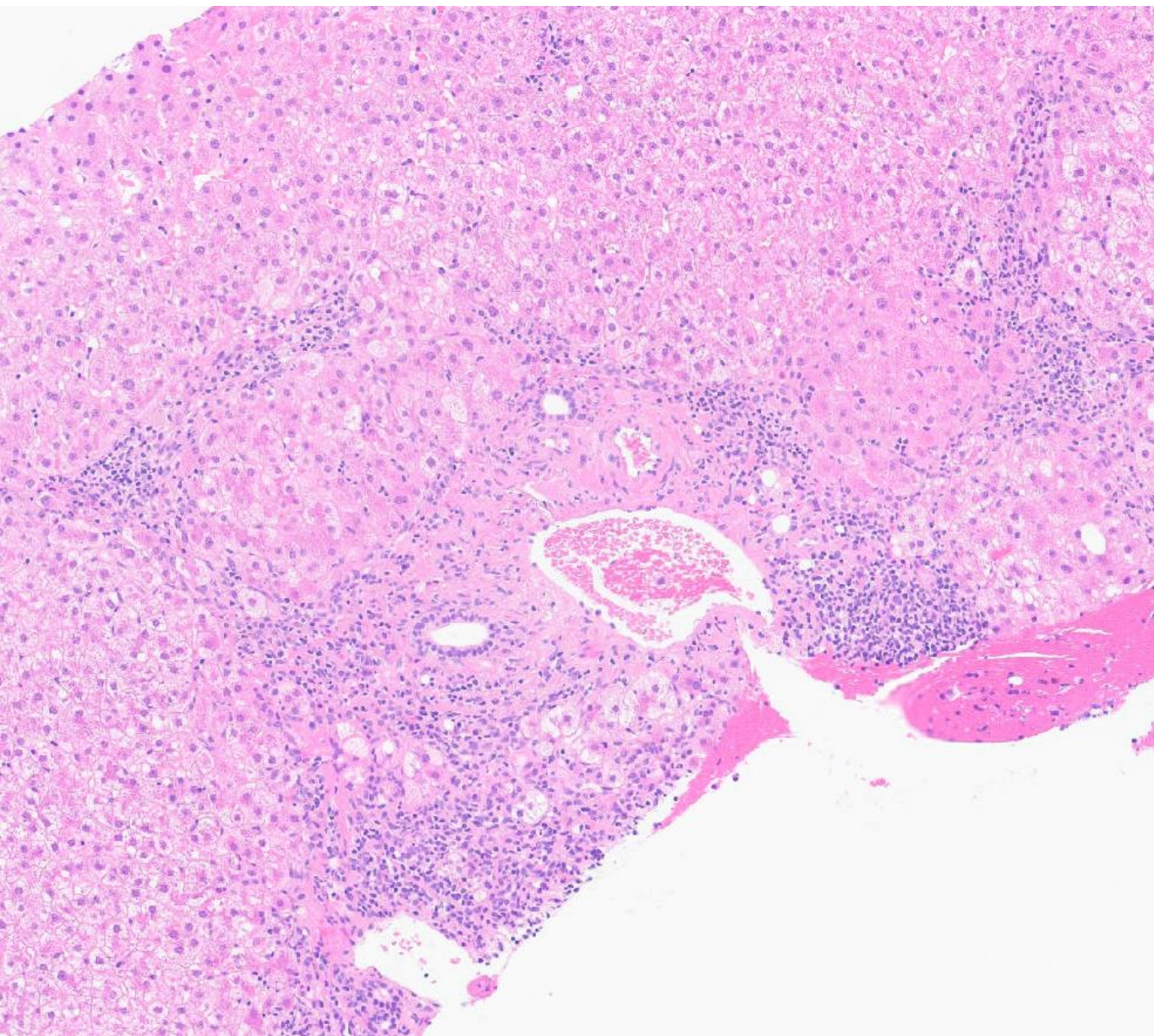


Severe portal inflammation –  
focal interface activity

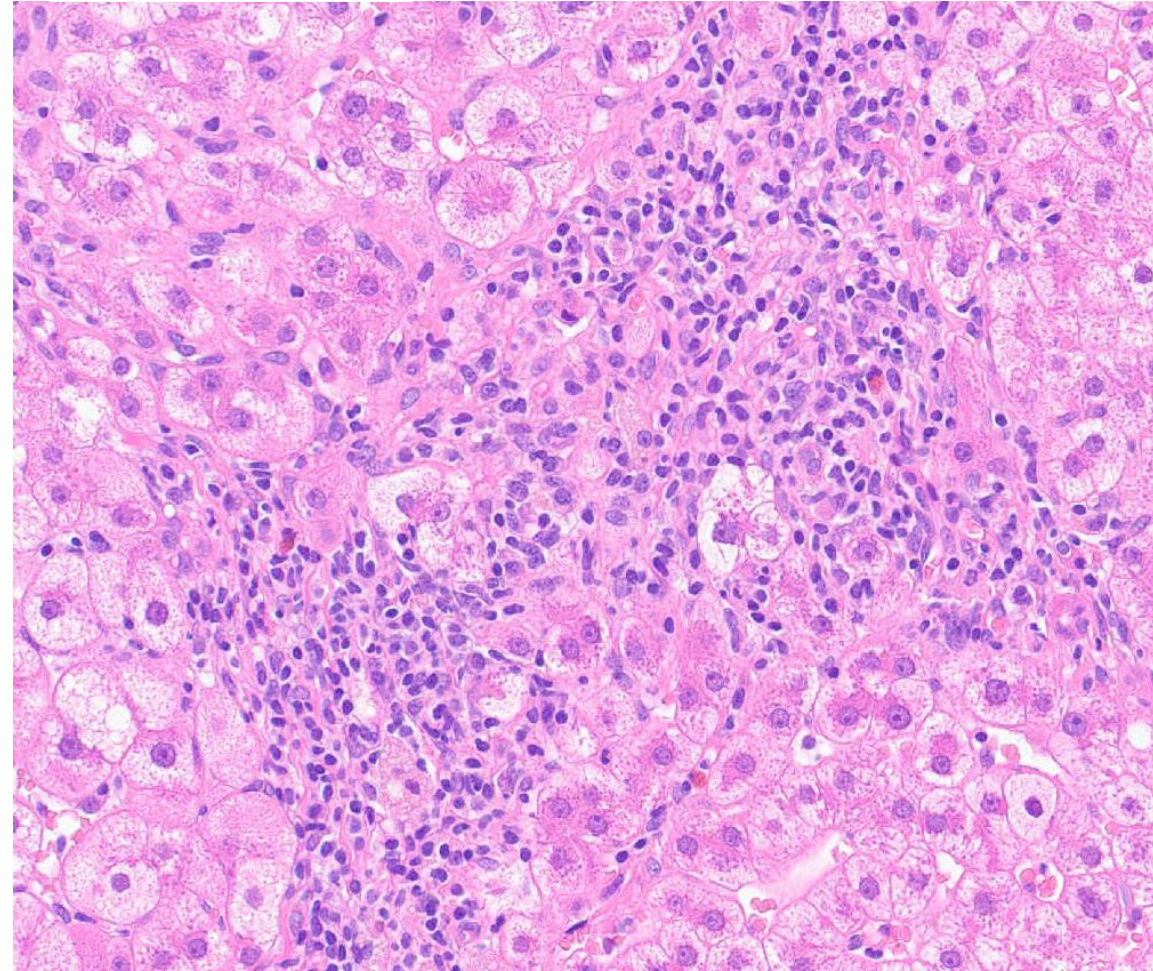


Prominent lobular inflammation –  
confluent necrosis

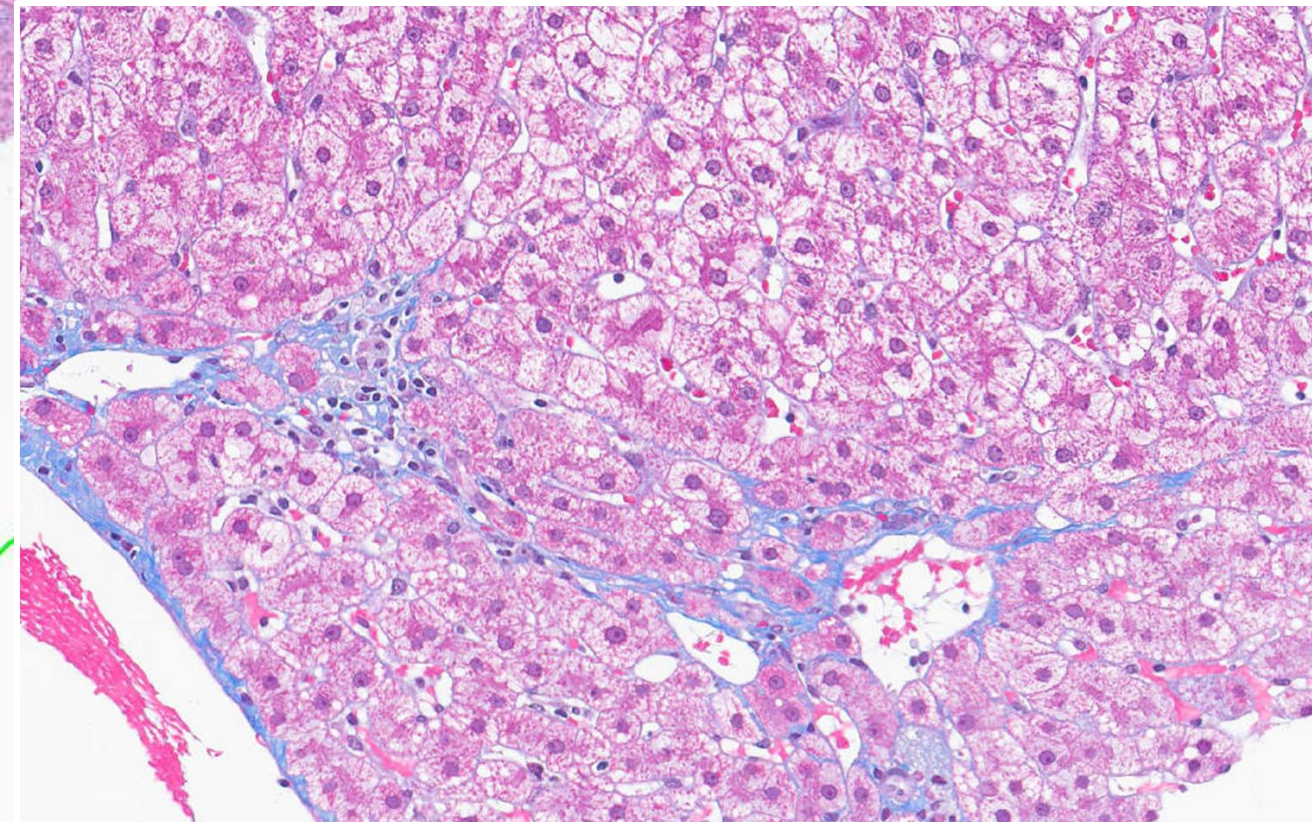
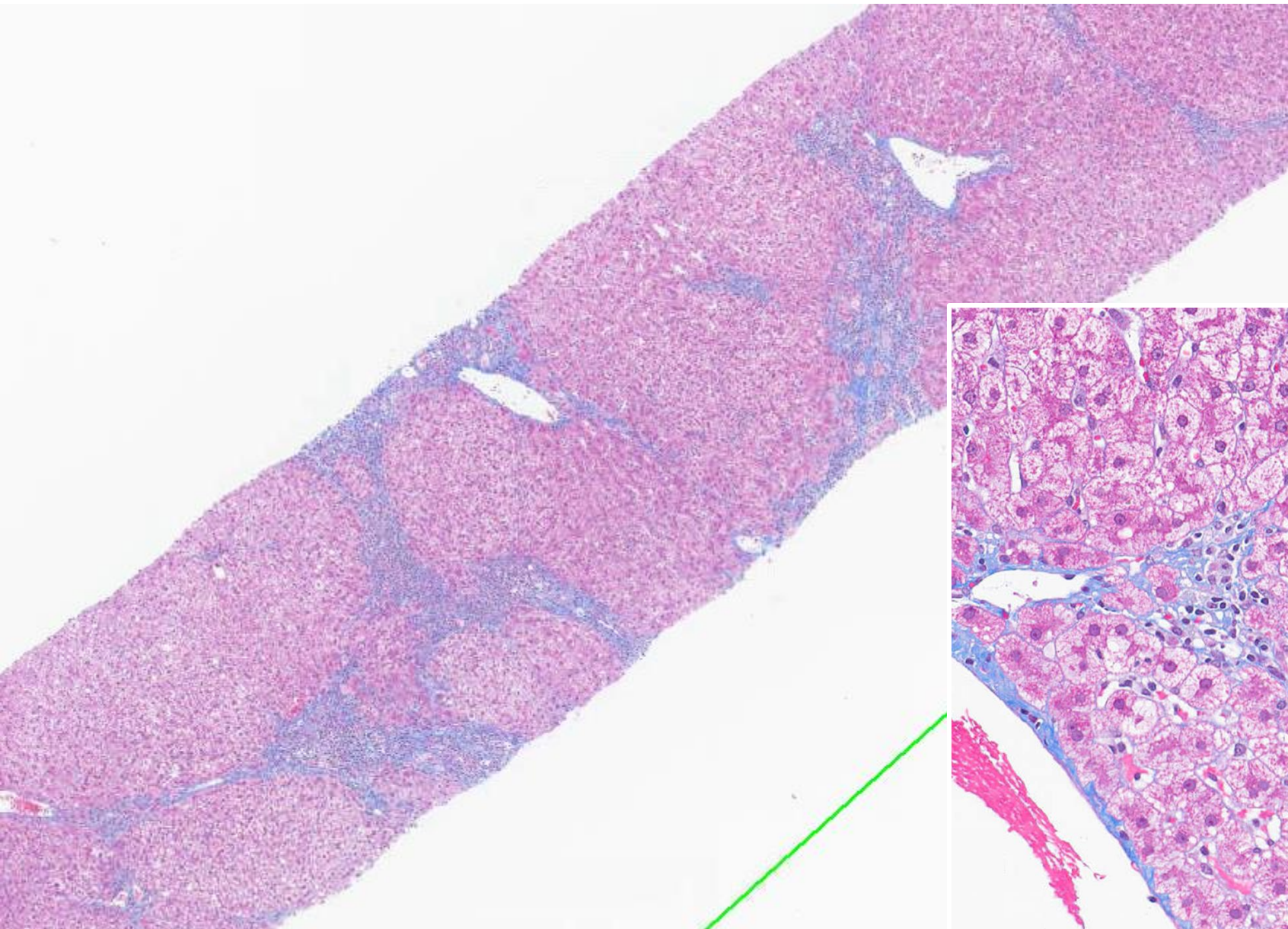
## Case 2



Prominent interface activity



Plasmacytes in the lobular infiltrate

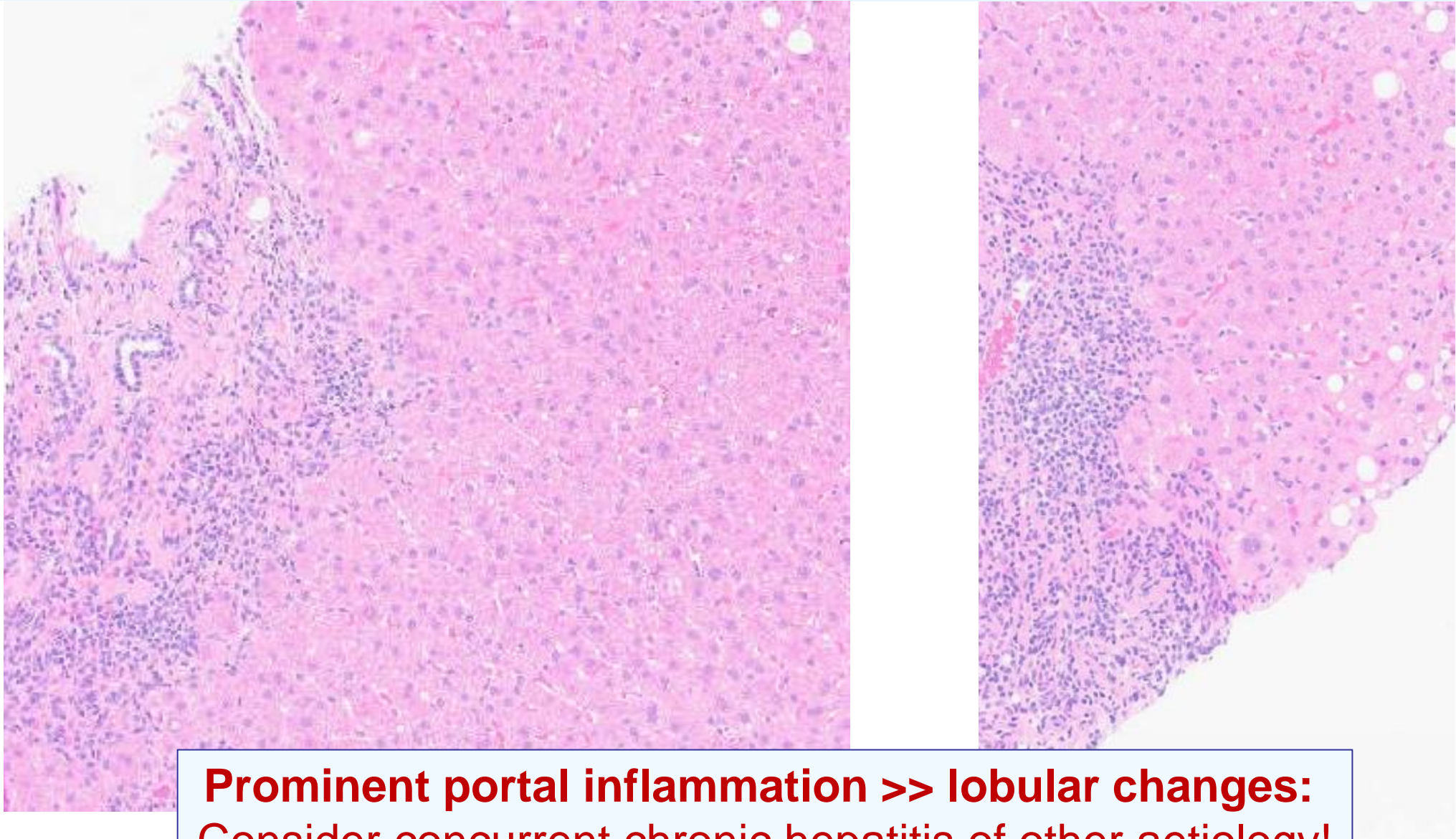


**Mild nonalcoholic steatohepatitis with bridging fibrosis**

**Prominent portal/periportal inflammation and overall pattern of injury raise suspicion of concurrent chronic hepatitis (viral, autoimmune, other ?)**

# Increased portal inflammation in NAFLD/NASH

## When to suspect a second pathology?



**Prominent portal inflammation >> lobular changes:  
Consider concurrent chronic hepatitis of other aetiology!**

# Take home messages

## PORTAL INFLAMMATION IN NAFLD

- Mild/more than mild portal inflammation is very frequent in NAFLD
- In untreated cases, is related to more severe disease and features of the metabolic syndrome in both adults and children
- In treated NASH, is a feature of disease resolution
- May have prognostic significance for NAFLD patient outcome

# Take home messages

## **NAFLD concurrent with another chronic liver disease**

- Is frequent due to the high prevalence of the metabolic syndrome
- Aggravates liver injury and accelerates fibrosis progression
- Differential diagnosis is difficult and no widely accepted histological criteria exist
- Helpful for diagnosing NASH concurrent with chronic hepatitis, in addition to steatosis, lobular inflammation and ballooning:
  - zone 3 sinusoidal/pericellular fibrosis
  - accentuation of necroinflammatory injury in zone 3
- Suspect concurrent chronic hepatitis in NAFLD when **portal inflammation is more prominent than lobular changes.... Talk to the hepatologist!**

---

# Non-alcoholic fatty liver disease

## Atlas of histological images

### Guidelines for diagnosis and scoring

---

Pierre Bedossa, Dina Tiniakos

<https://tinyurl.com/LITMUS-Histology>



Paul **NASH** (1889-1946)